Université de Paris

Hôpital Lariboisière
Hôpital Saint Louis
AP-HP.Nord

Place actuelle de la chirurgie dans la prise en charge de la rétinopathie diabétique

Aude Couturier

Service d'Ophtalmologie
Hôpital Lariboisière

Université de Paris

Chirurgie d’un patient diabétique

1. RDP compliquée: HdV, DRT
2. OM tractionnel
3. OM non tractionnel ?
4. Cataracte diabétique

Chirurgie d’un patient diabétique

1. RDP compliquée: HdV, DRT
2. OM tractionnel
3. OM non tractionnel ?
4. Cataracte diabétique

Objectifs de la vitrectomie dans la RDP

1. Supprimer l'opacité des milieux
2. Supprimer les tractions
   a. antéro-postérieures
   b. tangentielles
3. Traiter les déhiscences
4. Pratiquer ou compléter la PPR
5. Adjuvants à la vitrectomie

Les techniques évoluent

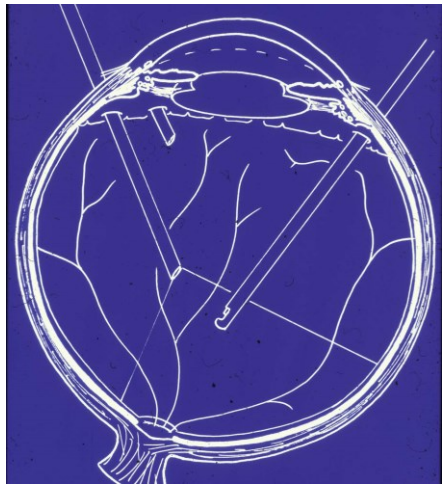

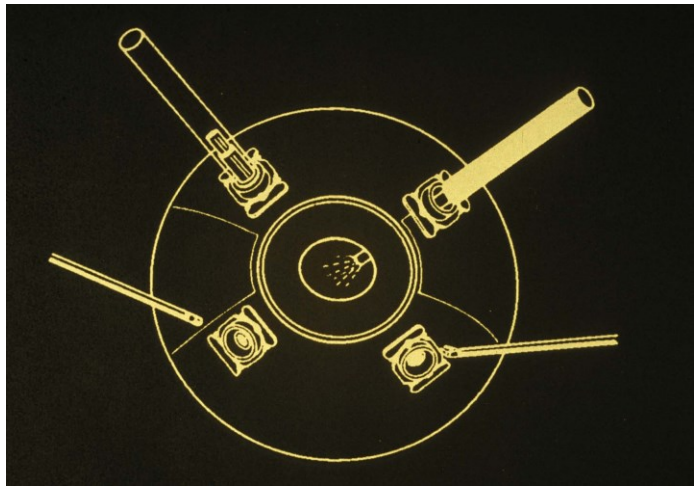

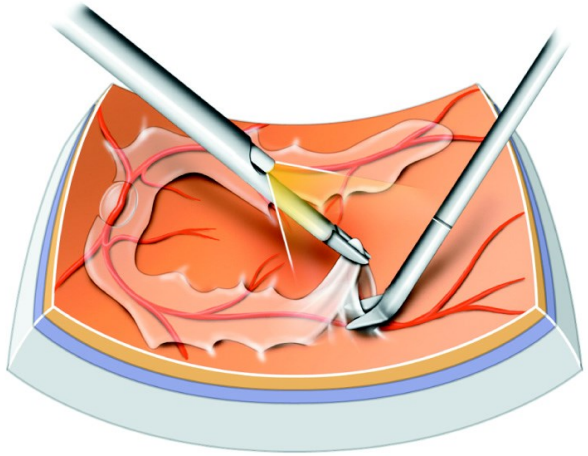

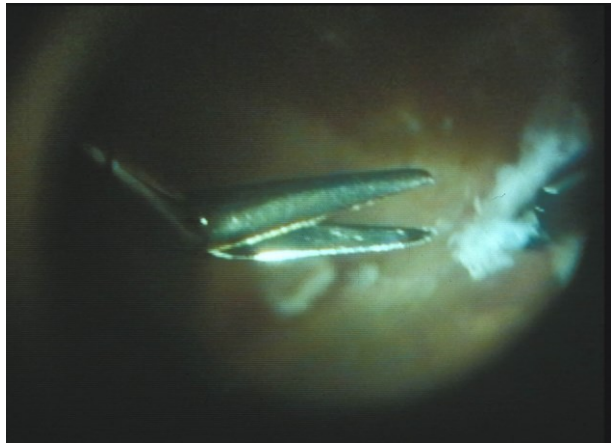

Université de Paris

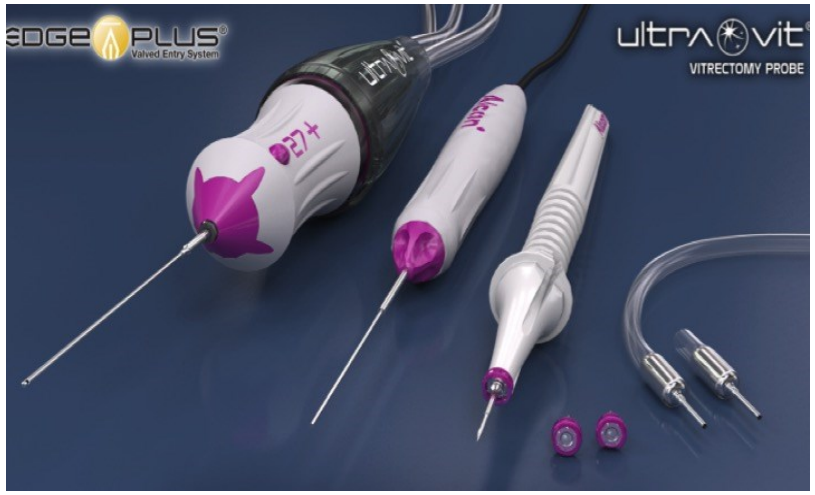

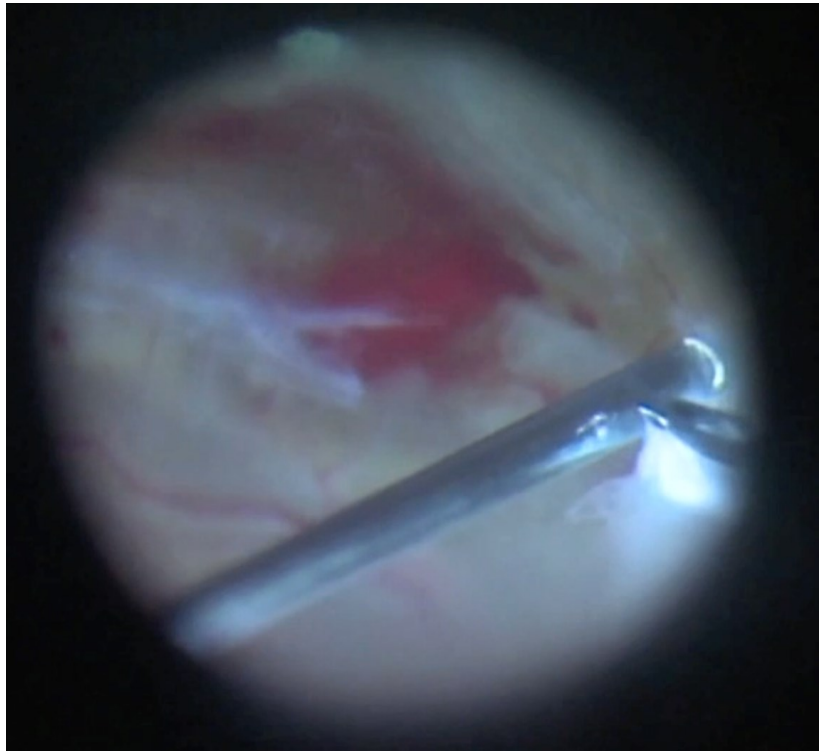

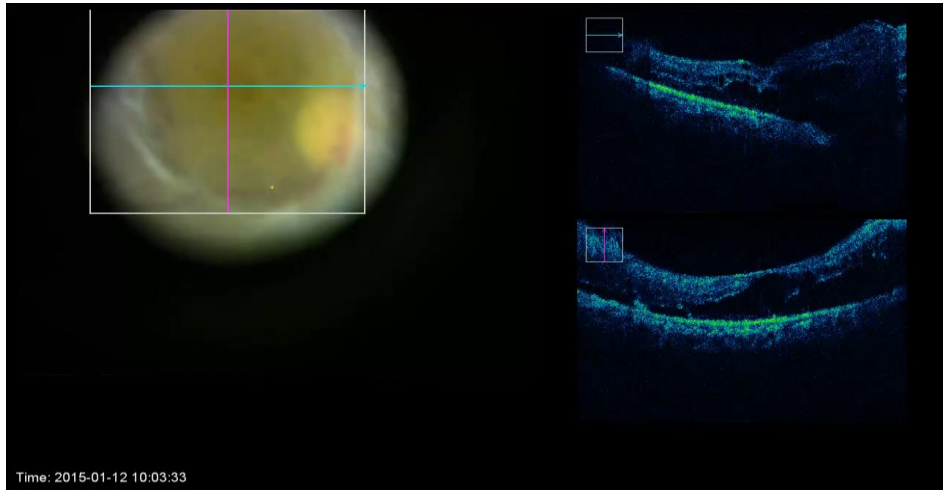

niversité
e Paris

Les indications de vitrectomie

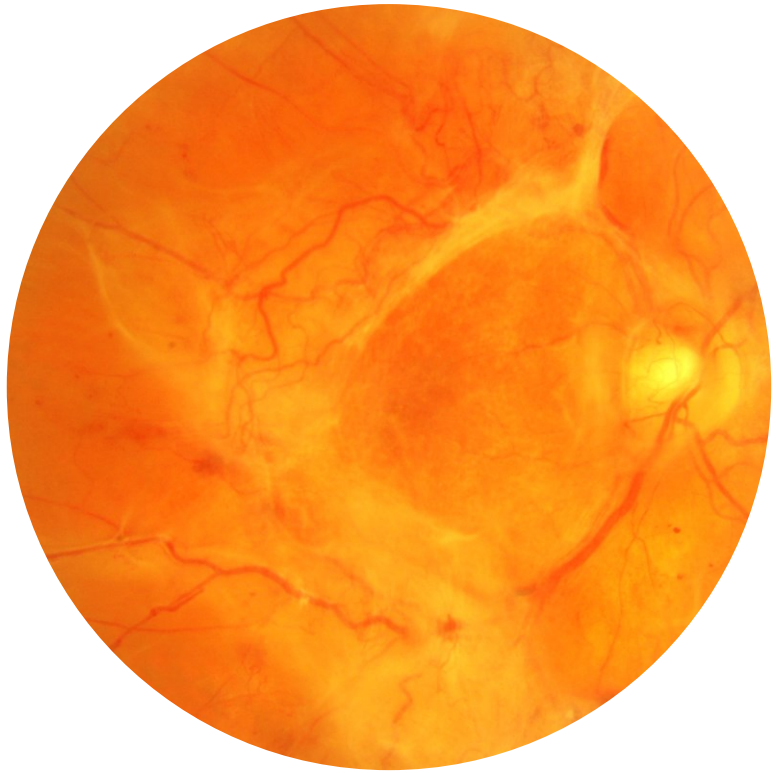

- Hémorragie du vitré persistante
- DR tractionnel maculaire
- DR mixte
- OM tractionnel

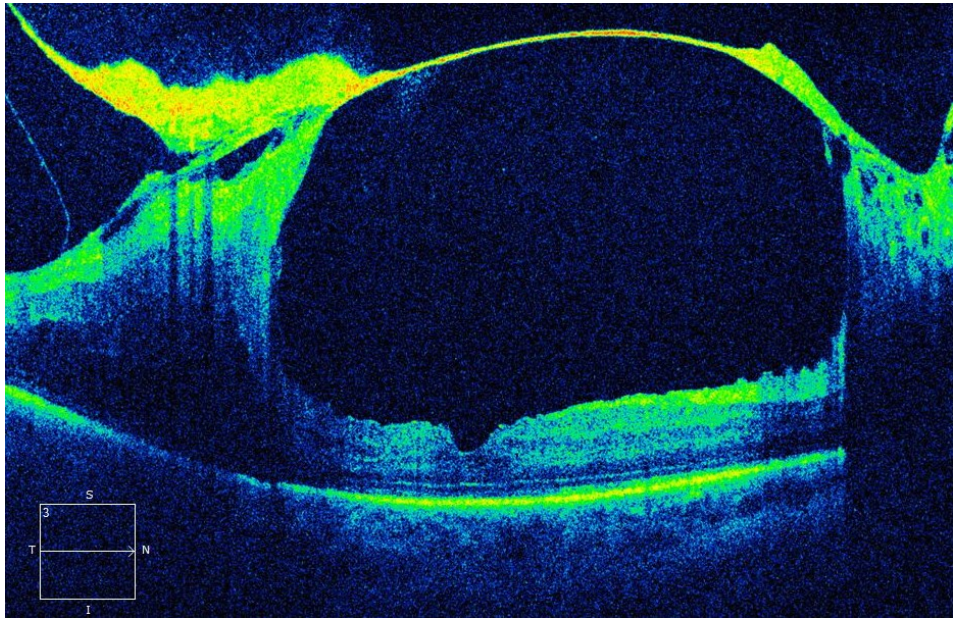

- On n’opère pas:
  - DR extra-maculaire
  - DR maculaire ancien > 1 an
  - Hémorragie du vitré minime

RDP compliquée d'HdV et/ou DRT

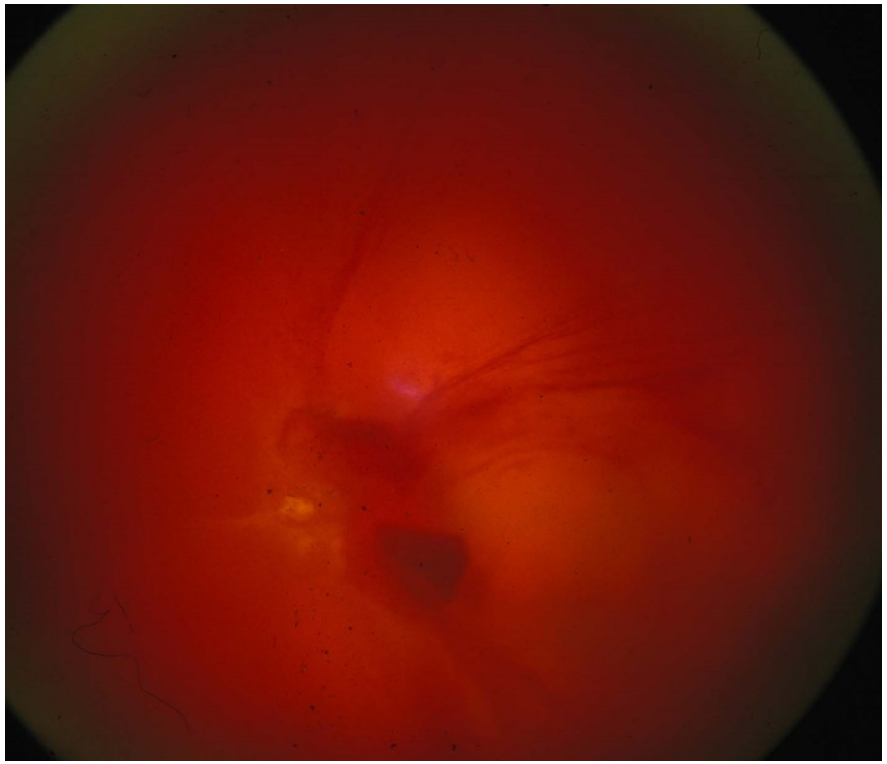

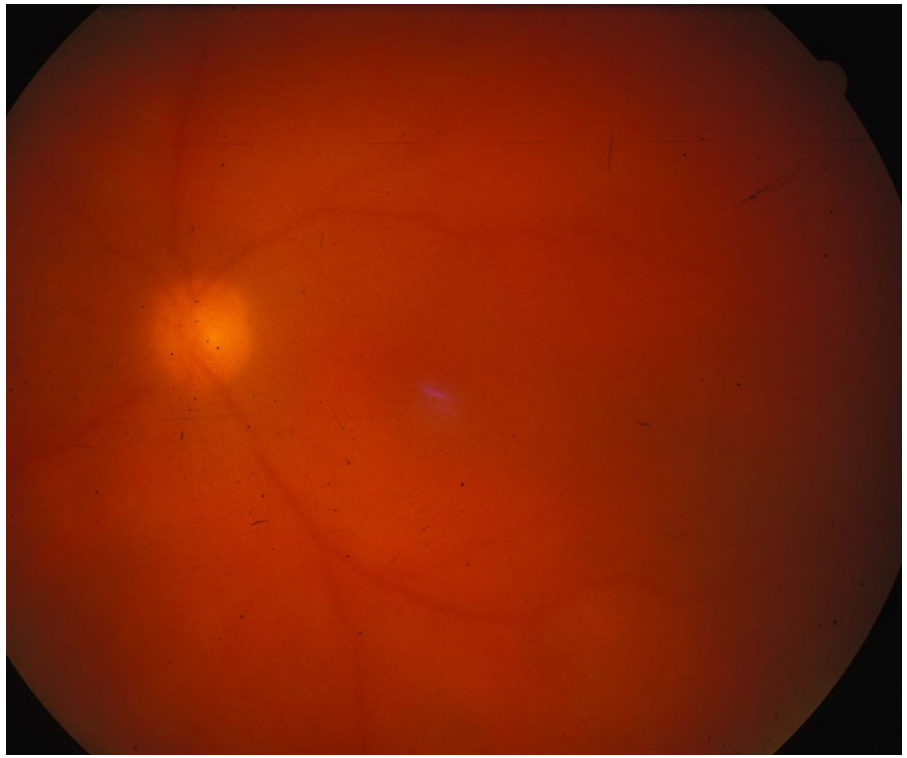

Université de Paris

RDP compliquée d'HdV et/ou DRT

- Le degré d'urgence dépend
  - **du TERRAIN +++** (monophtalme ? Jeune avec rétinopathie floride ?)
  - de la présence d'une PPR sous-jacente
  - de la présence d'une rubéose irienne

Indications -Délais

- CHIRURGIE URGENTE : **DR mixte**

- CHIRURGIE RAPIDE < 1 mois
  - **HdV** empêchant la réalisation d'une PPR, **en l'absence de PPR** préalable, d'autant plus rapidement qu'il existe une rubéose irienne (dans les 7 jours)
  - **Rétinopathie floride** du jeune diabétique type 1 avec proliférations néovasculaires extensives malgré PPR et anti-VEGF / HIV
  - **DR tractionnel fovéolaire** (souvent BAV assez progressive)
    - Acuité visuelle post op ≥ 1/10ème : 10%
  - **Hématome** maculaire rétro hyaloidien

Indications-Délais

- CHIRURGIE PROGRAMMEE
  - **HdV avec PPR**, attendre 1 à 2 mois
  - **HdV récidivantes** : 2 à 3 /an
  - Récidive d'hémorragie intra-cavitaire post-vitrectomie
  - Fibrose pré rétinienne / MER avec OMD

⇒Intérêt de l'échographie en cas d'HdV empêchant l'analyse du FO

⇒Délais (DR ou non)

⇒Temps opératoire (dissection de prolifération fibro-vasculaire ?)

Intérêt de l'échographie B

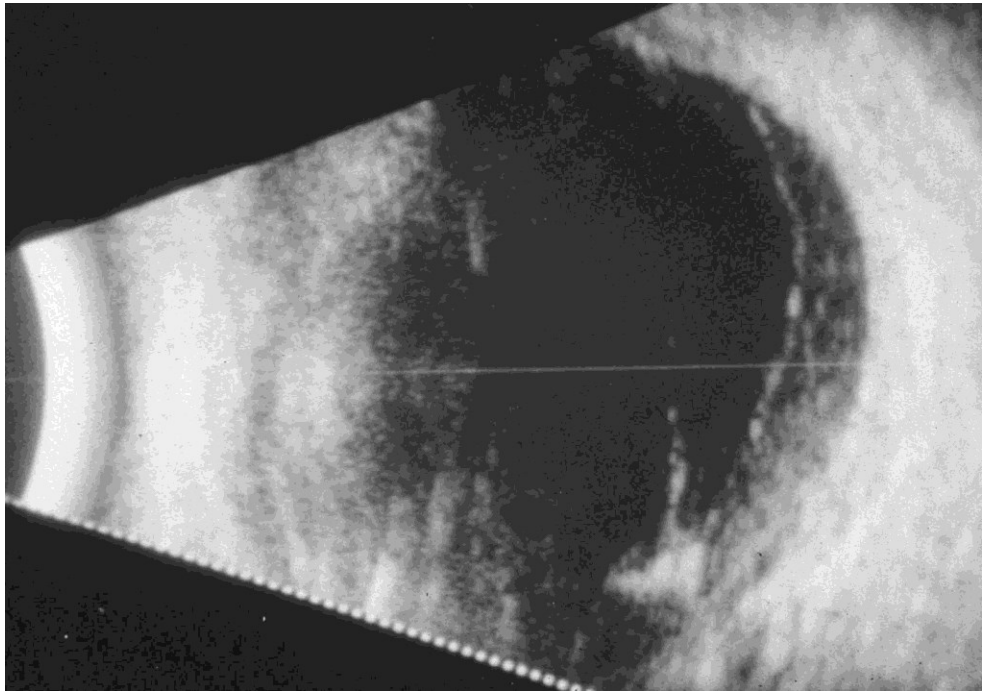

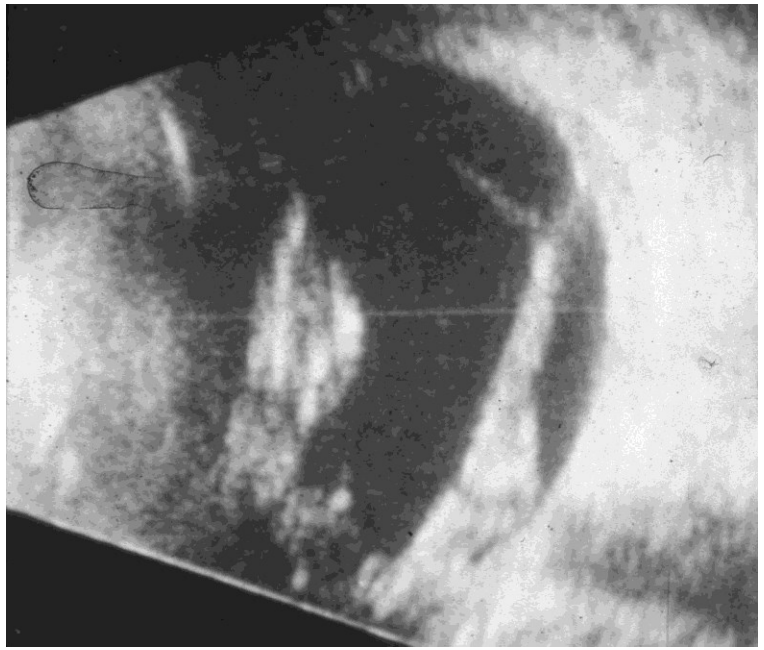

Table top

En pratique

⇒ Timing de la chirurgie à MODULER selon le caractère MONOPHTALME, jeune etc….

- On opèrera plus rapidement si patient monophtalme et/ou jeune
- Toujours prendre le temps d'expliquer les bénéfices/risques
- Privilégier l'anesthésie GENERALE si jeune ou monophtalme (réduit le saignement per op)

On n’opère pas

- DRT extra-maculaire
  - risque extension à la macula faible
    - 6 mois : 8%
    - 1 an : 14%
    - 2 ans : 21%
    - 3 ans : 23,5%
- DRT avec macula off mais ancien >1 an
- HdV minime

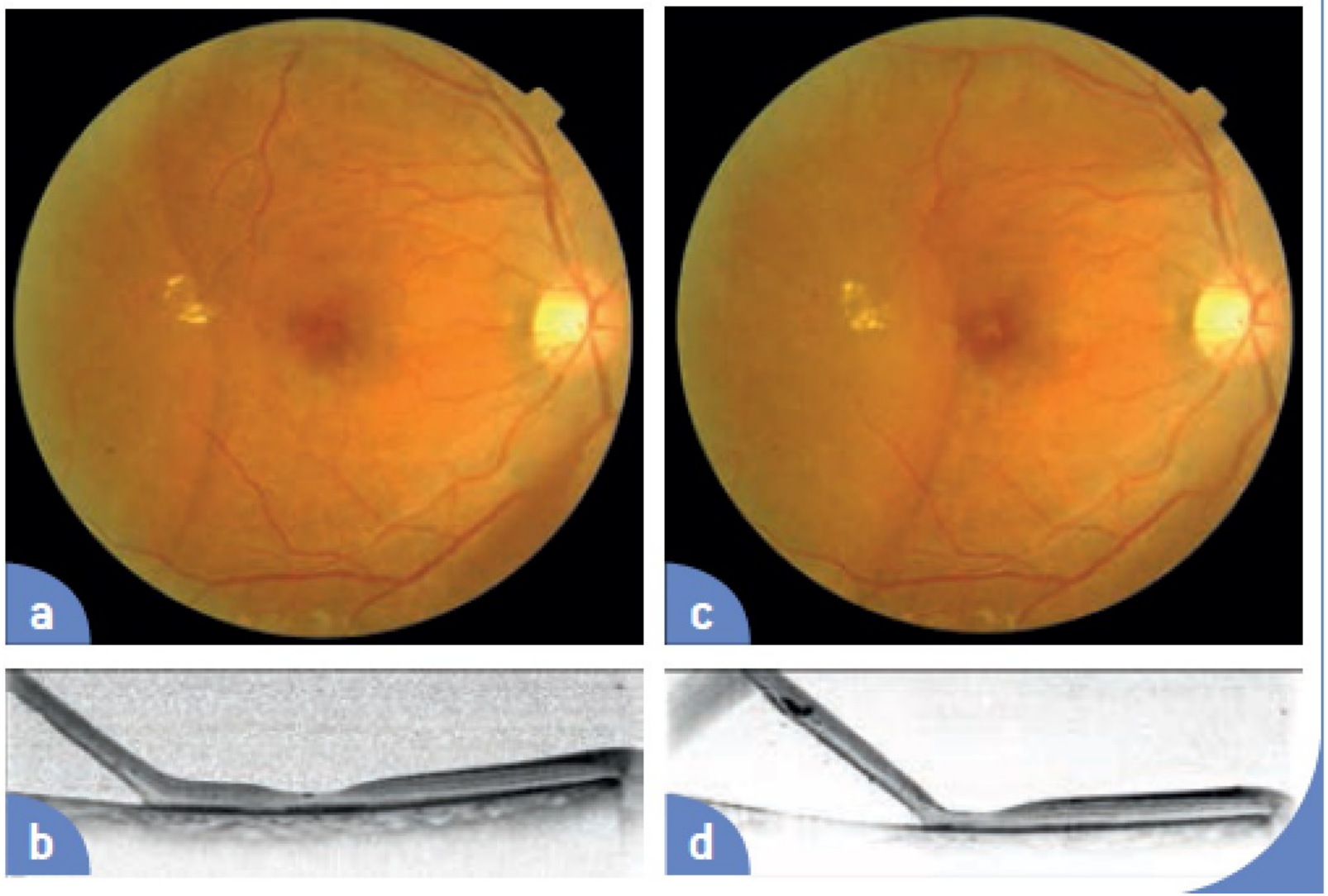

DR mixte à progression rapide vers la macula = opérer rapidement

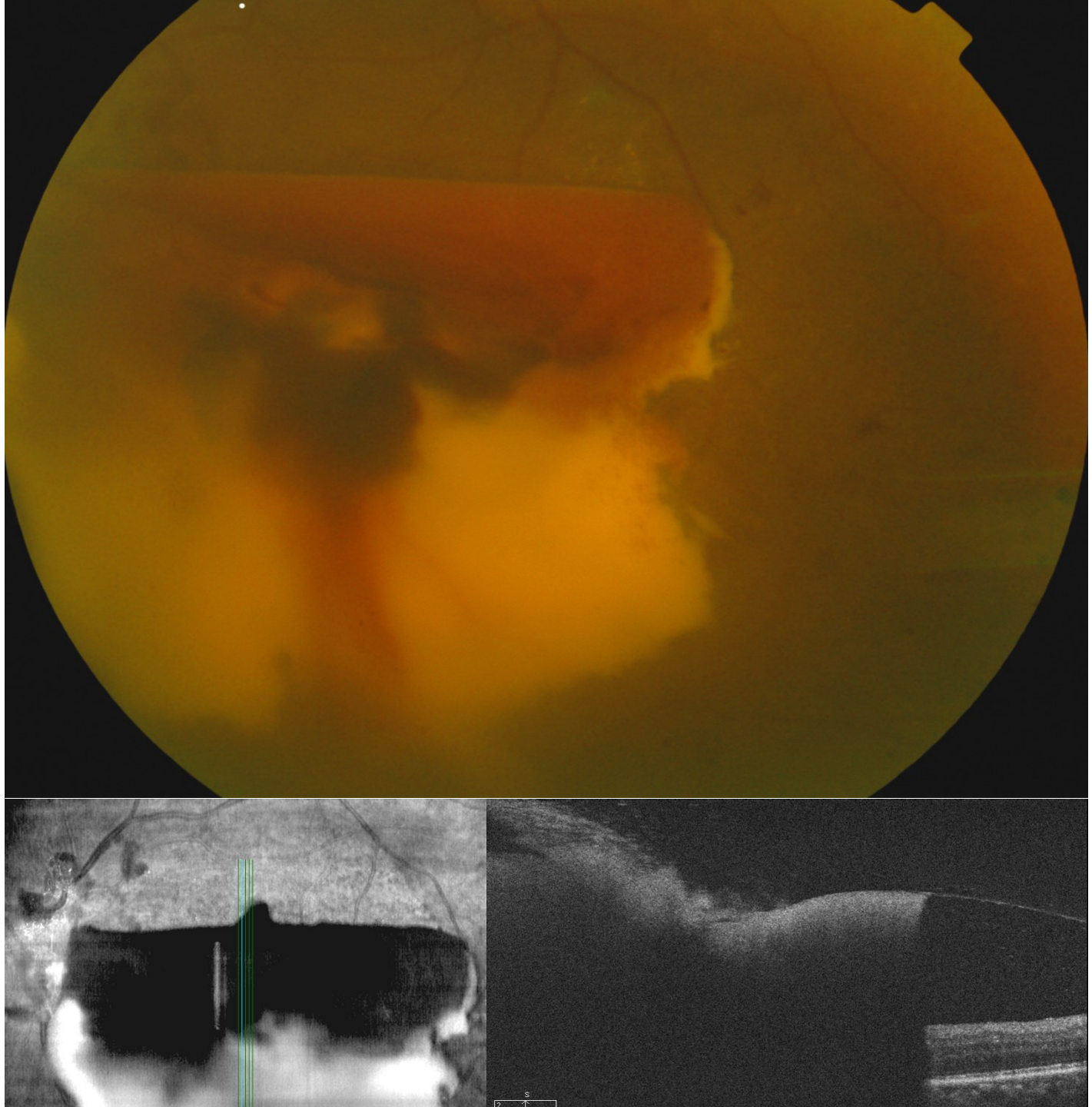

Université de Paris

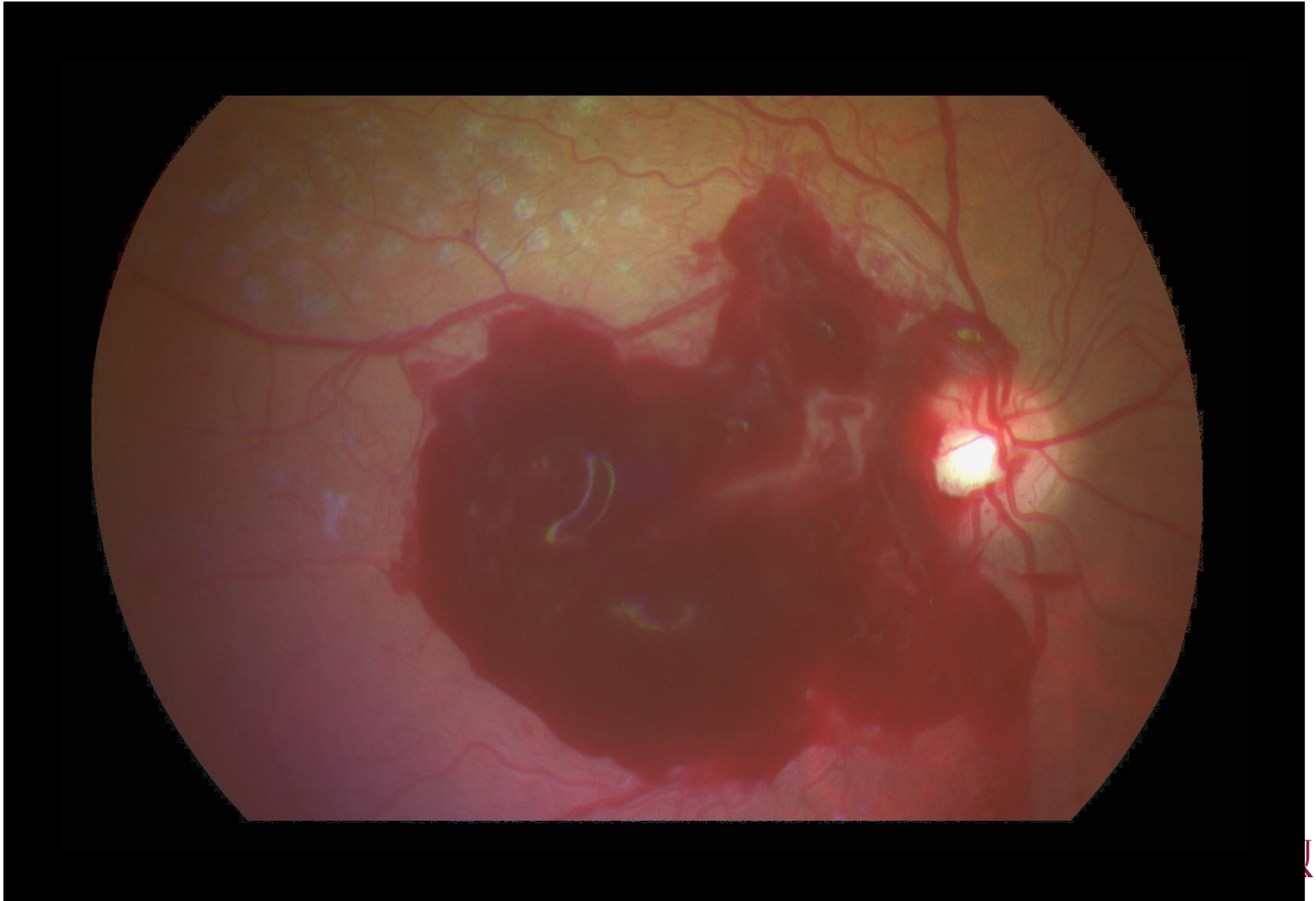

Université de Paris

Jeune homme 29 ans
DT1
Pré dialyse
Phtyse sur GNV OG

BAV OD depuis
quelques semaines

AV : 7/10e P2f

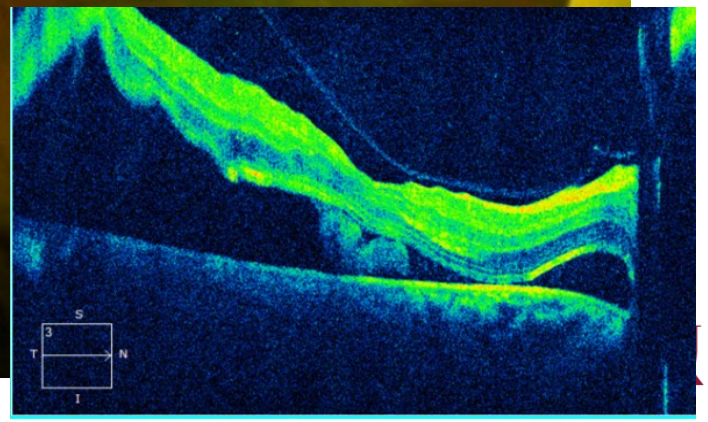

Université
de Paris

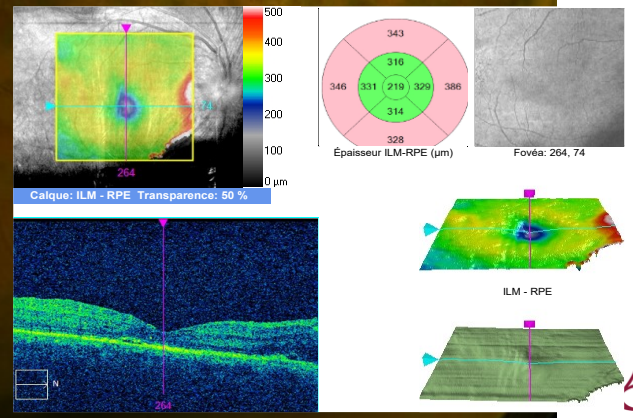

AV : 7/10e P2f

Université de Paris

Le succès anatomique n’est pas synonyme de succès visuel

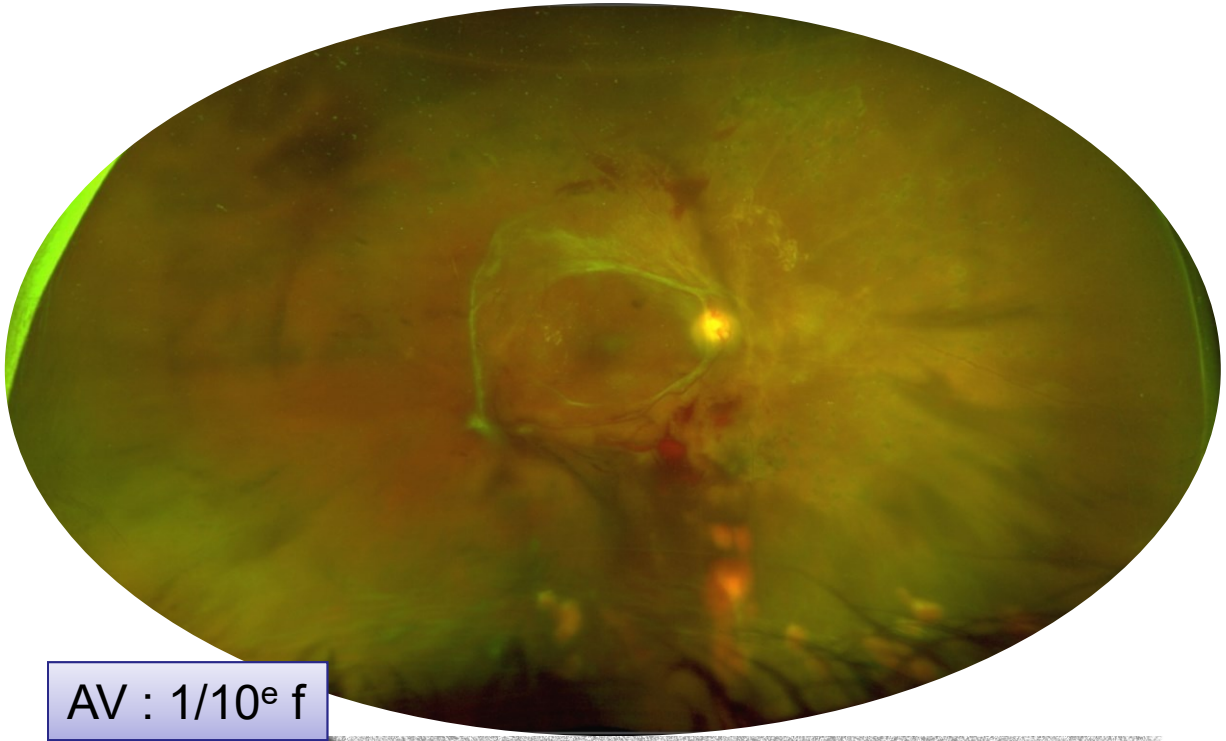

AV : 1/10e f

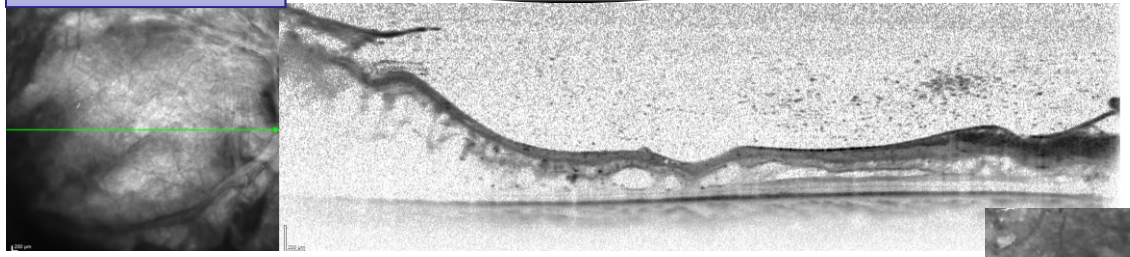



M+2 post op : CLD

Université de Paris

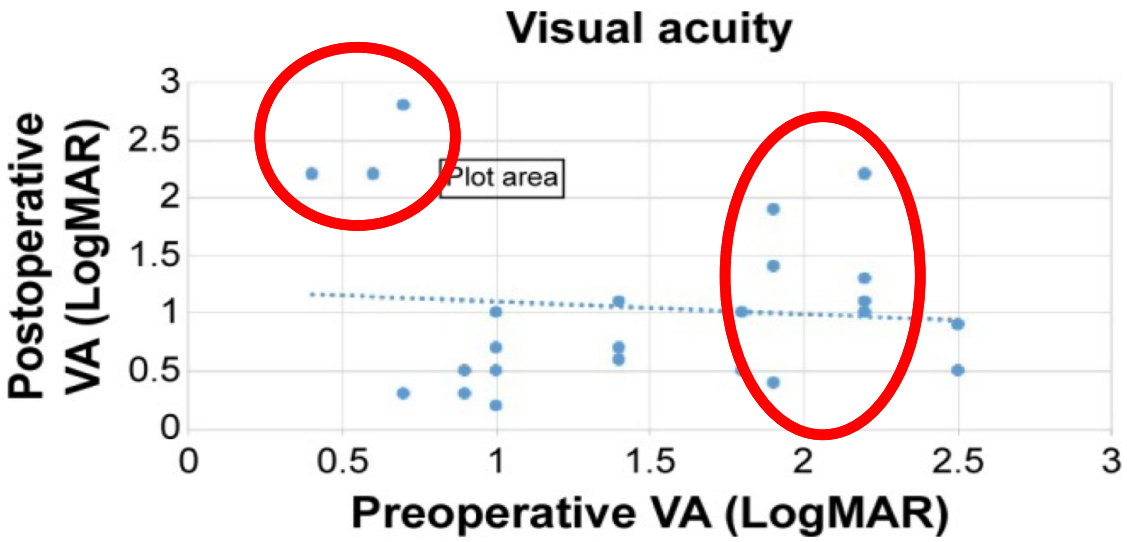

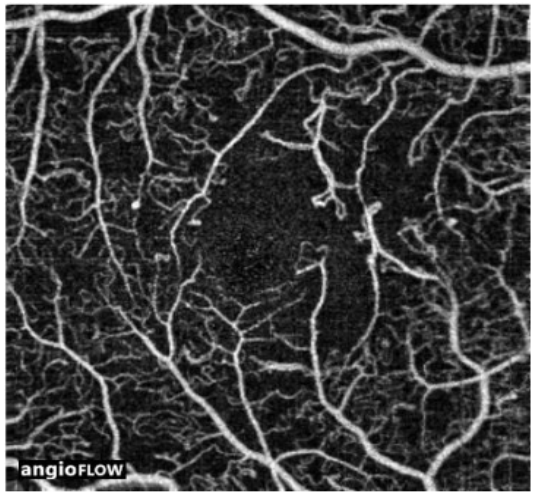

Linear regression analysis of the relationship between preoperative and postoperative visual acuity (VA).

Note: No correlation was observed between these two variants (Pearson's correlation coefficient,

Pas de corrélation entre AV initiale pré-op et finale (pronostic est lié à la viabilité du tissu rétinien sous jacent)

⇒durée d'évolution

⇒Degré d'ischémie maculaire

⇒État du nerf optique

⇒Lésions d'hypoperfusion per op +++

RUBEOSE IRIENNE / facteur de mauvais pronostic

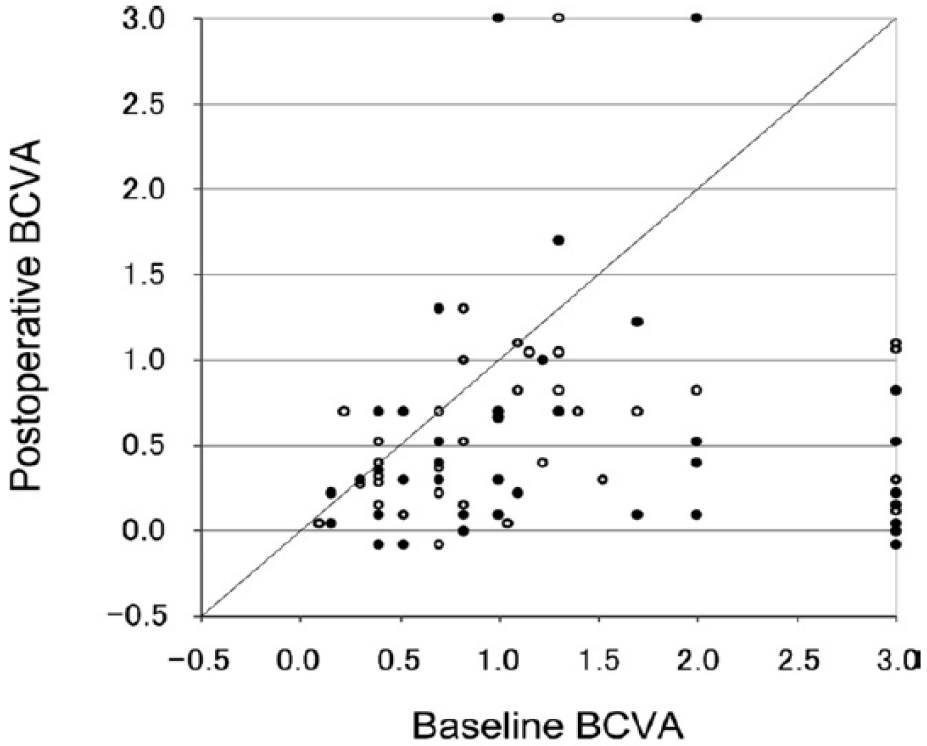

Université de Paris

Les techniques

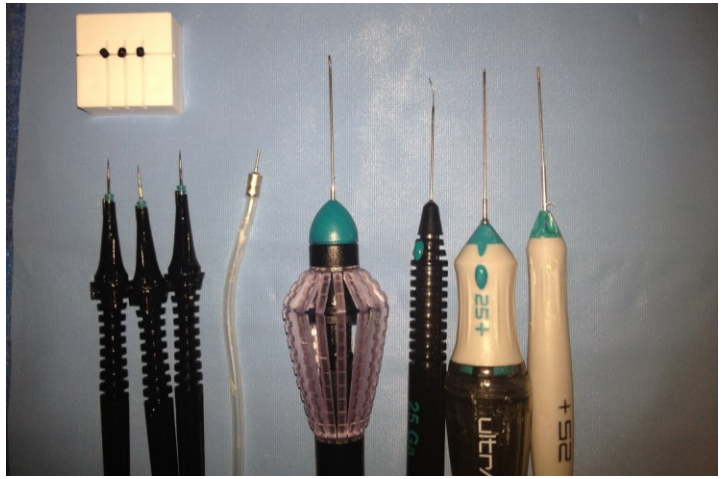

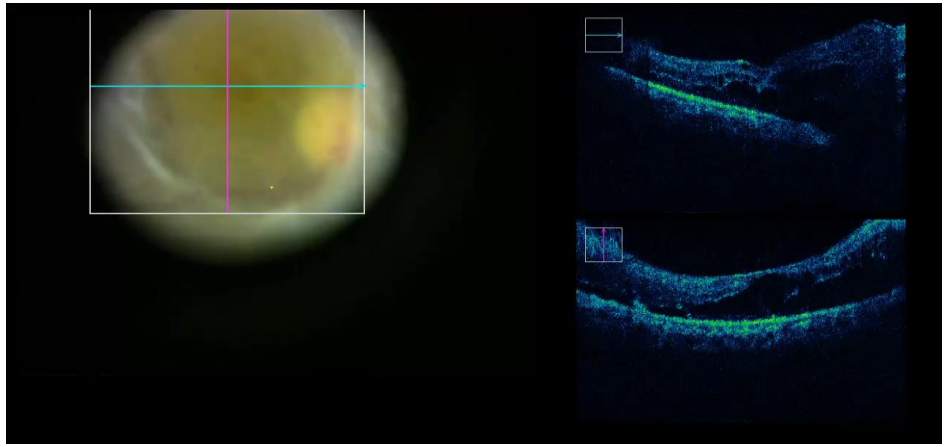

Université de Paris

Tcehnique : libérer les tractions antéropostérieures

- DPV partiel
- Prolifération fibrovasculaire devant le pôle postérieur
  - S’étendant sur la face postérieure de la hyaloïde partiellement décollée

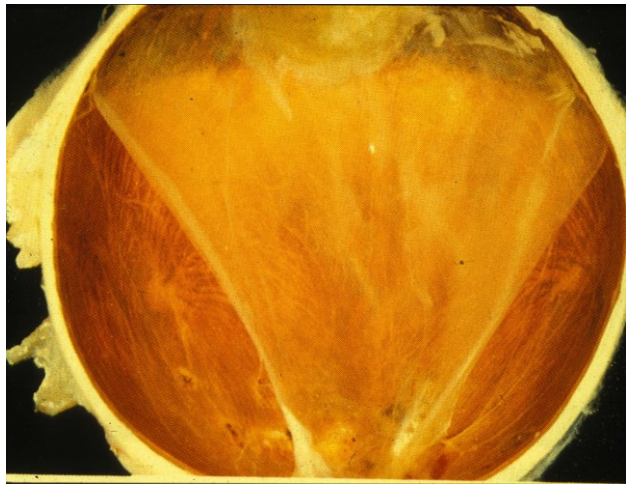

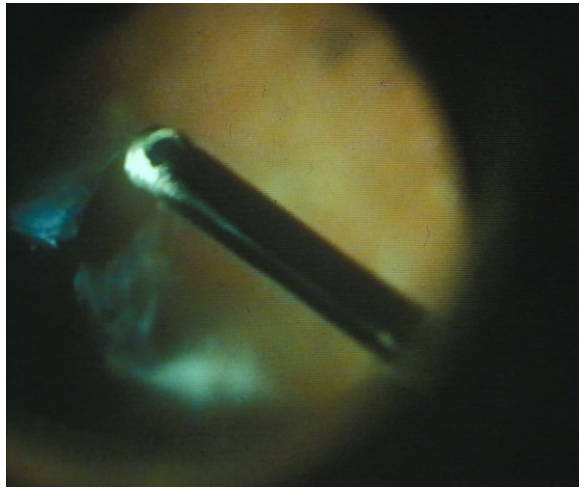

Libérer les tractions antéro-postérieures

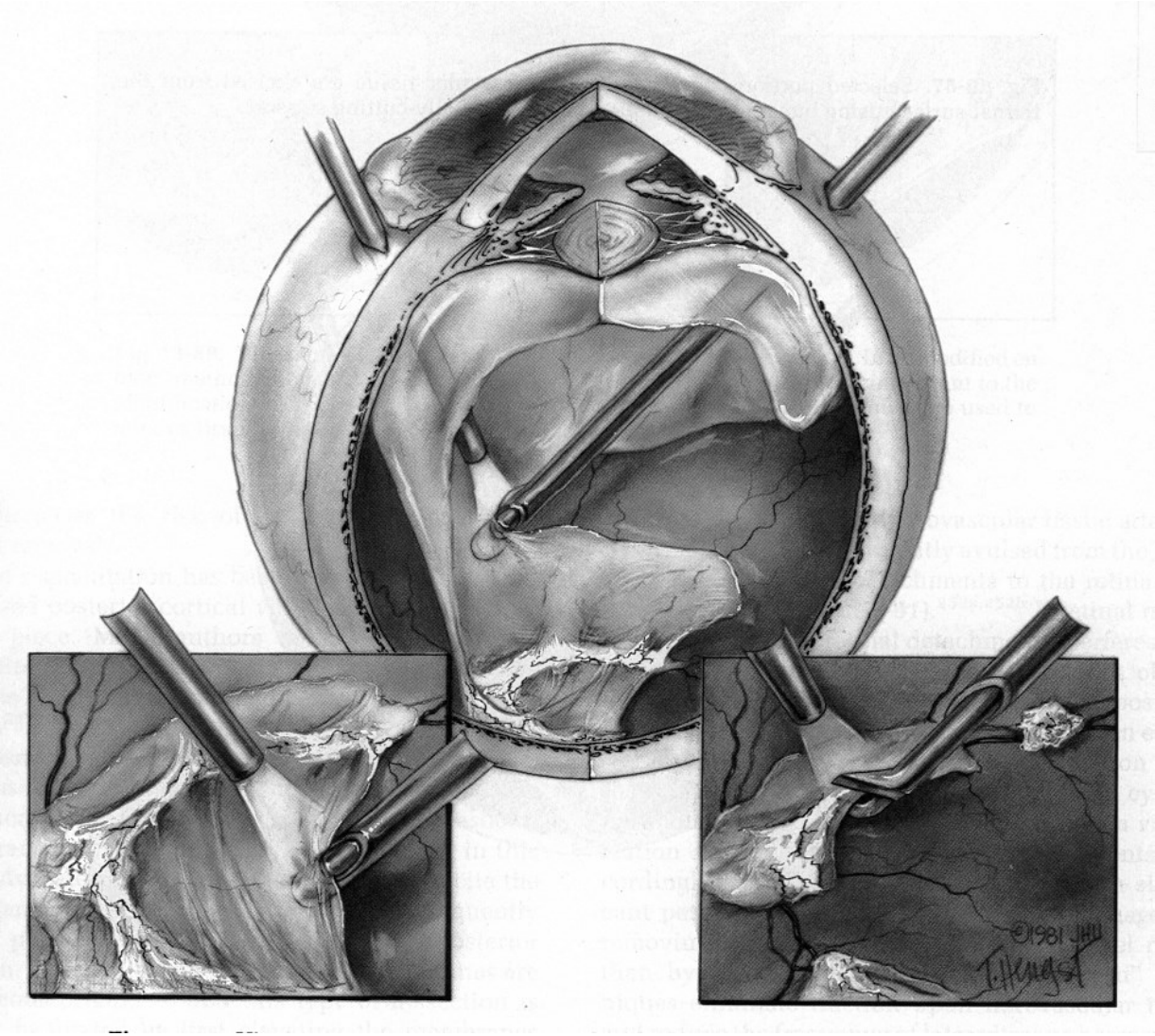

Université de Paris

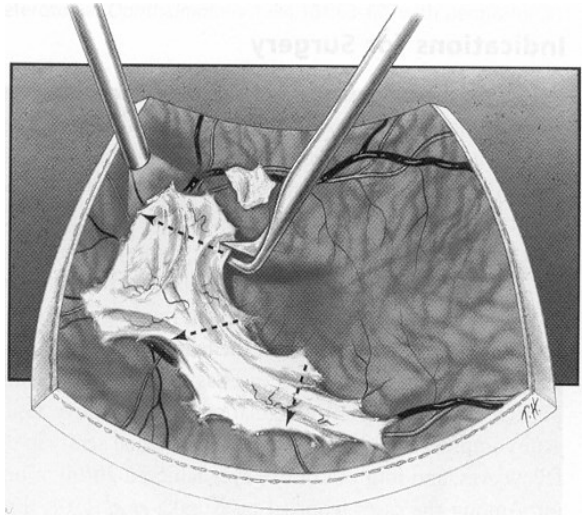

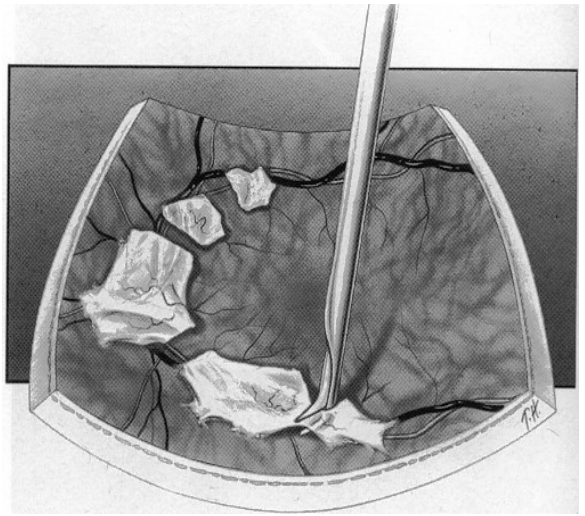

- segmentation

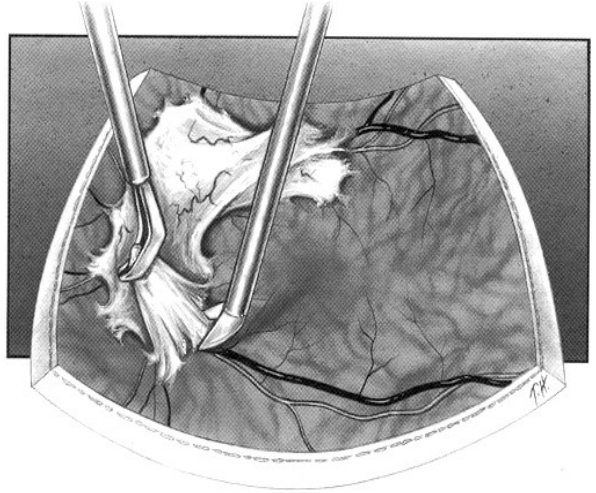

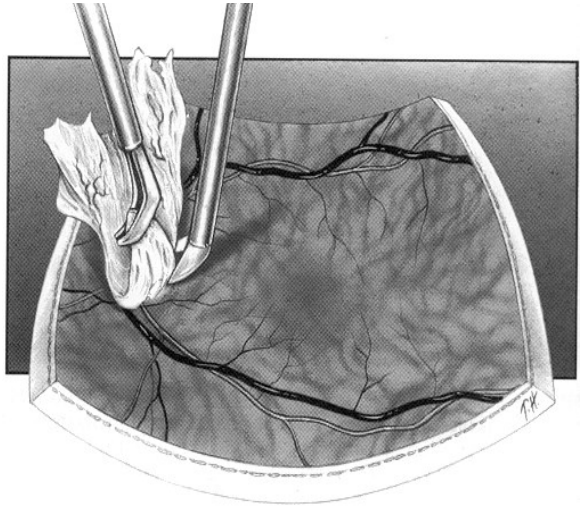

- délamination bimanuelle

Université de Paris

Segmentation

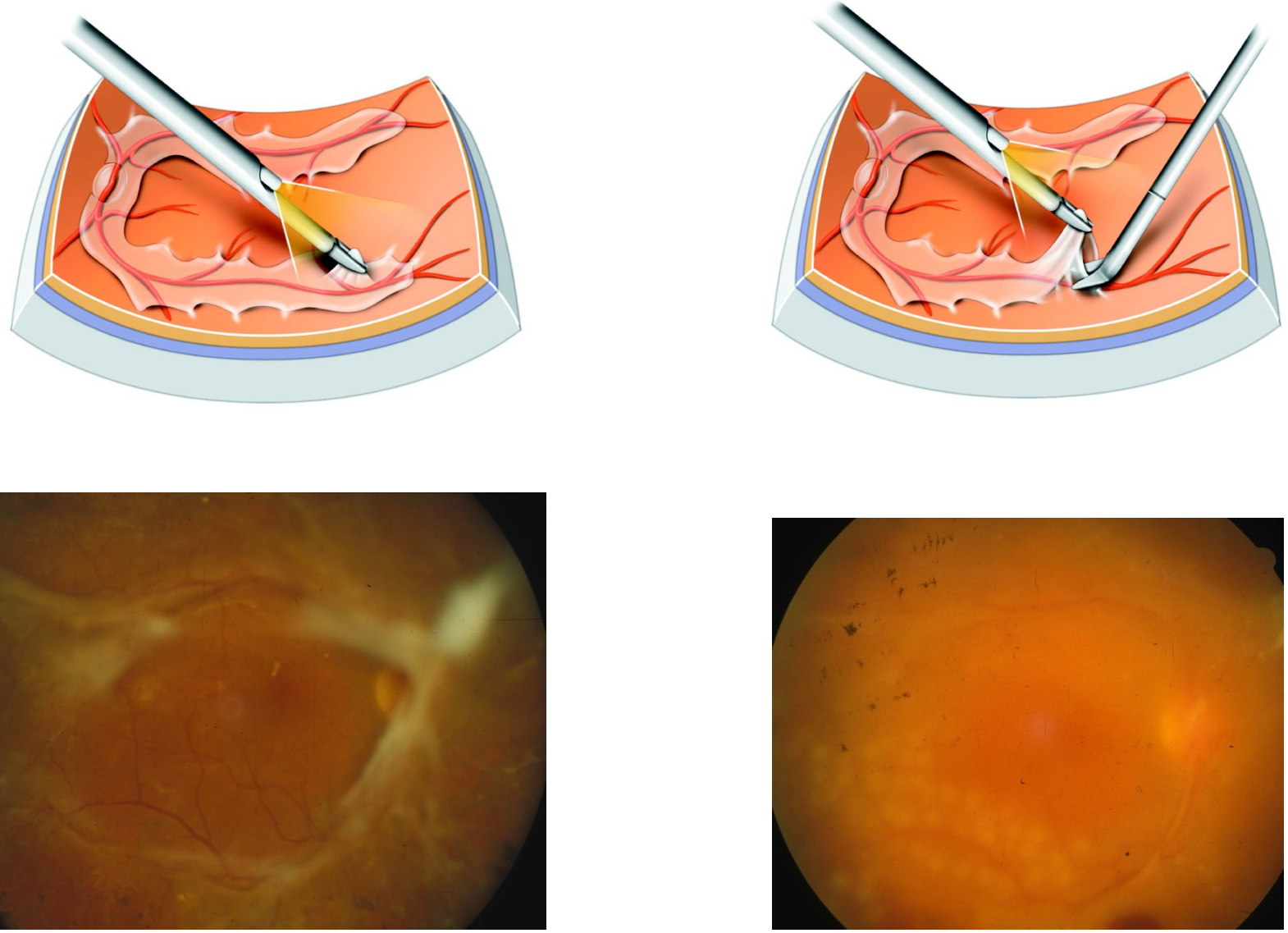

Délamination

Université de Paris

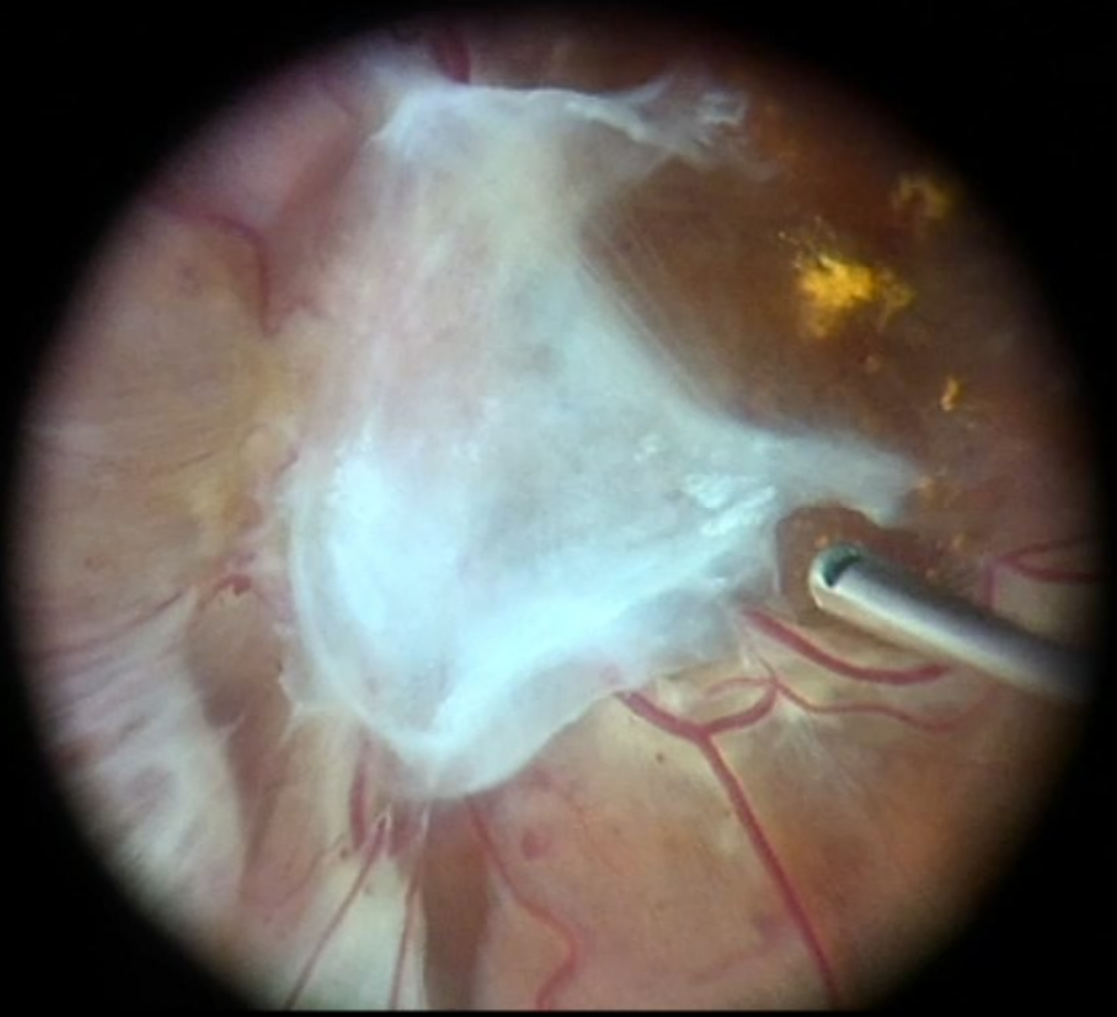

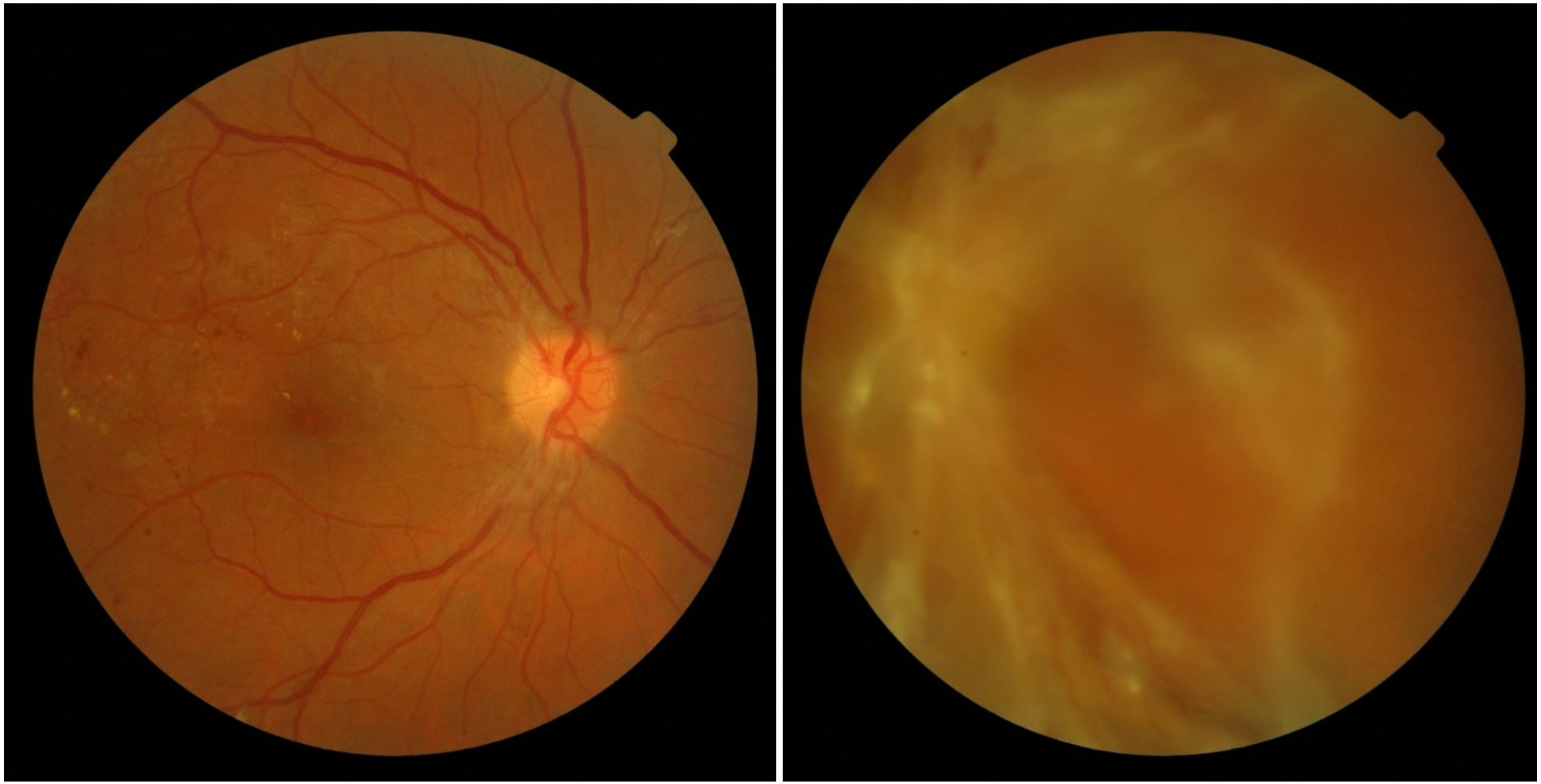

Université de Paris

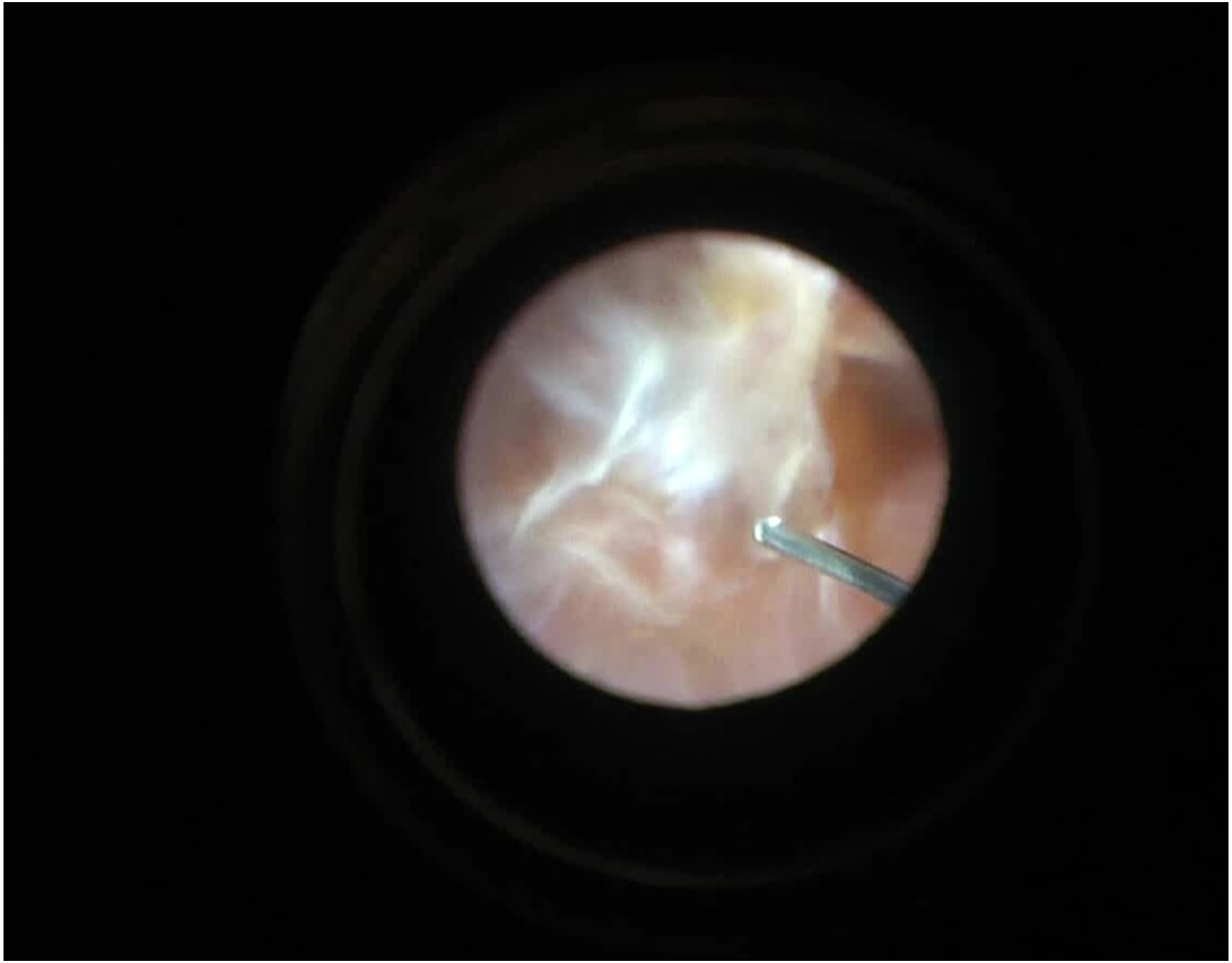

Université de Paris

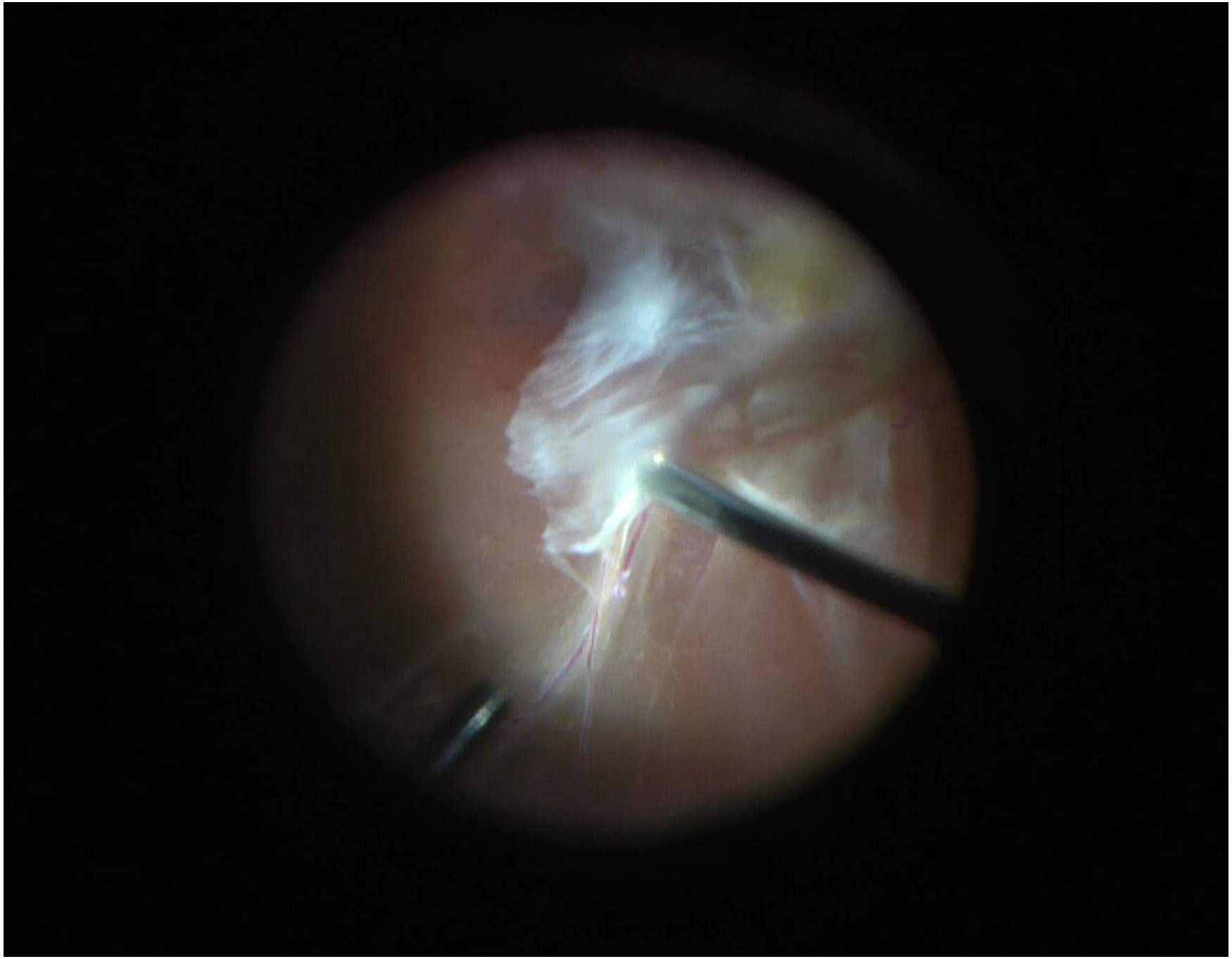

Université de Paris

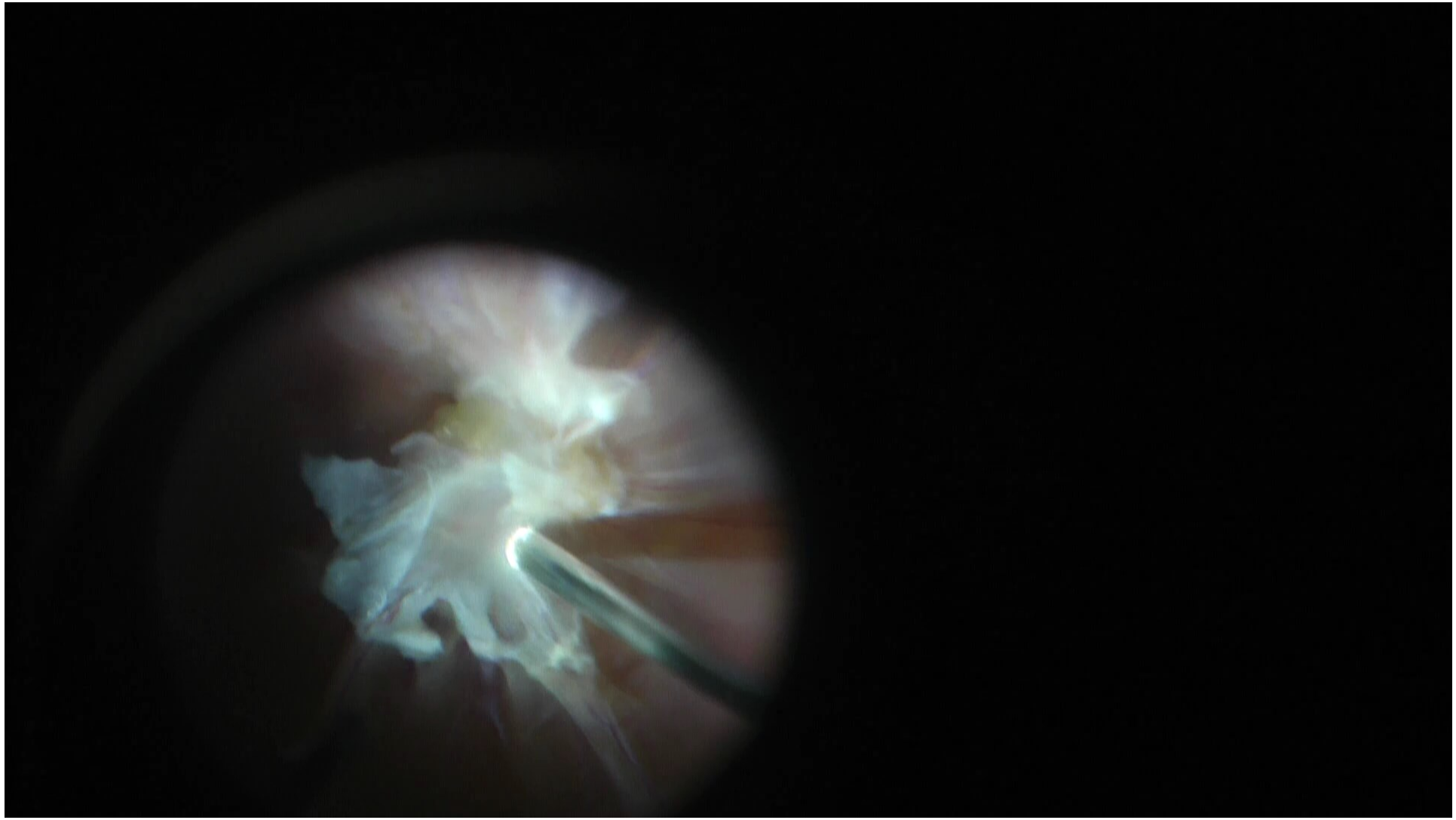

Université de Paris

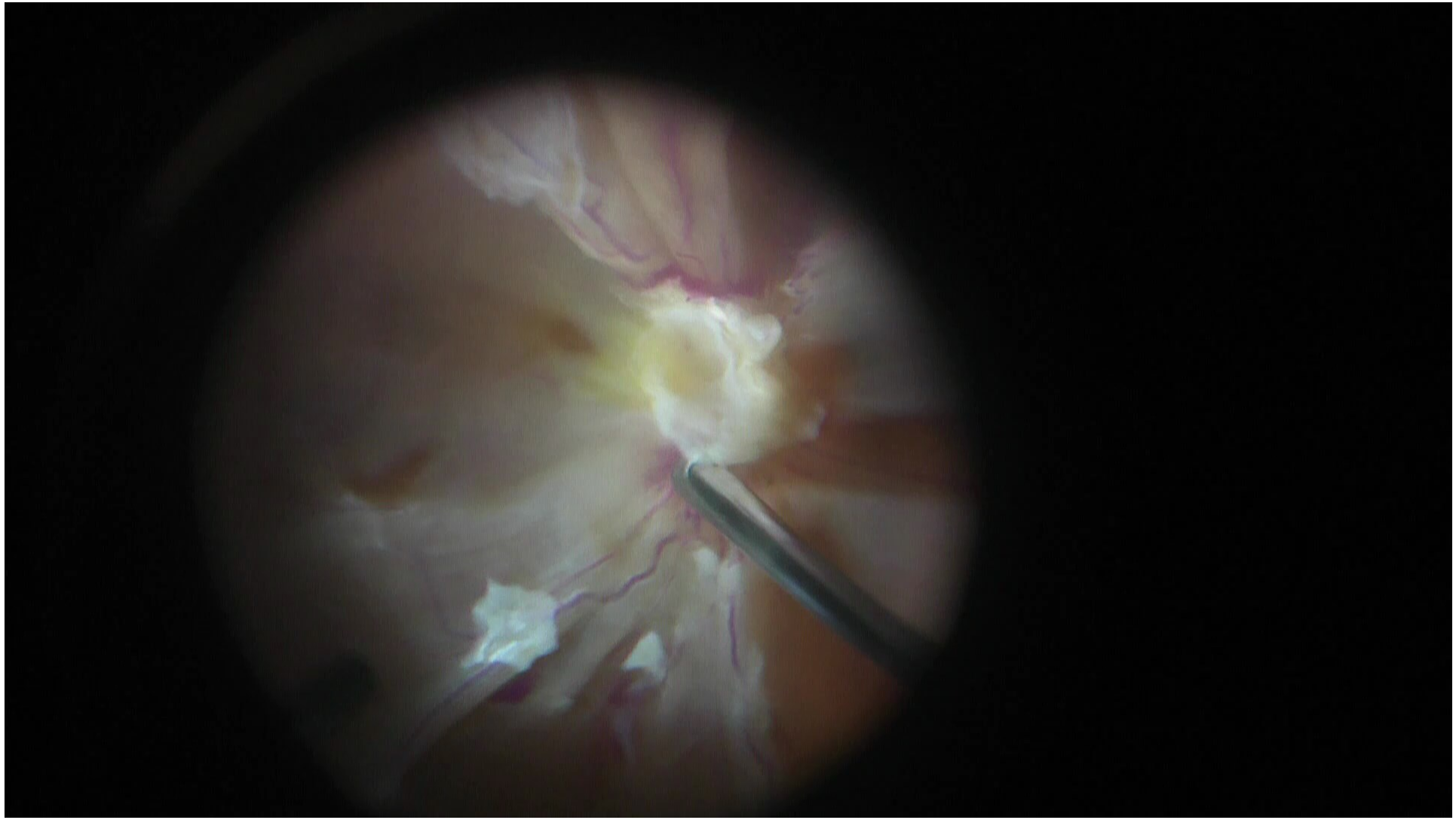

Université de Paris

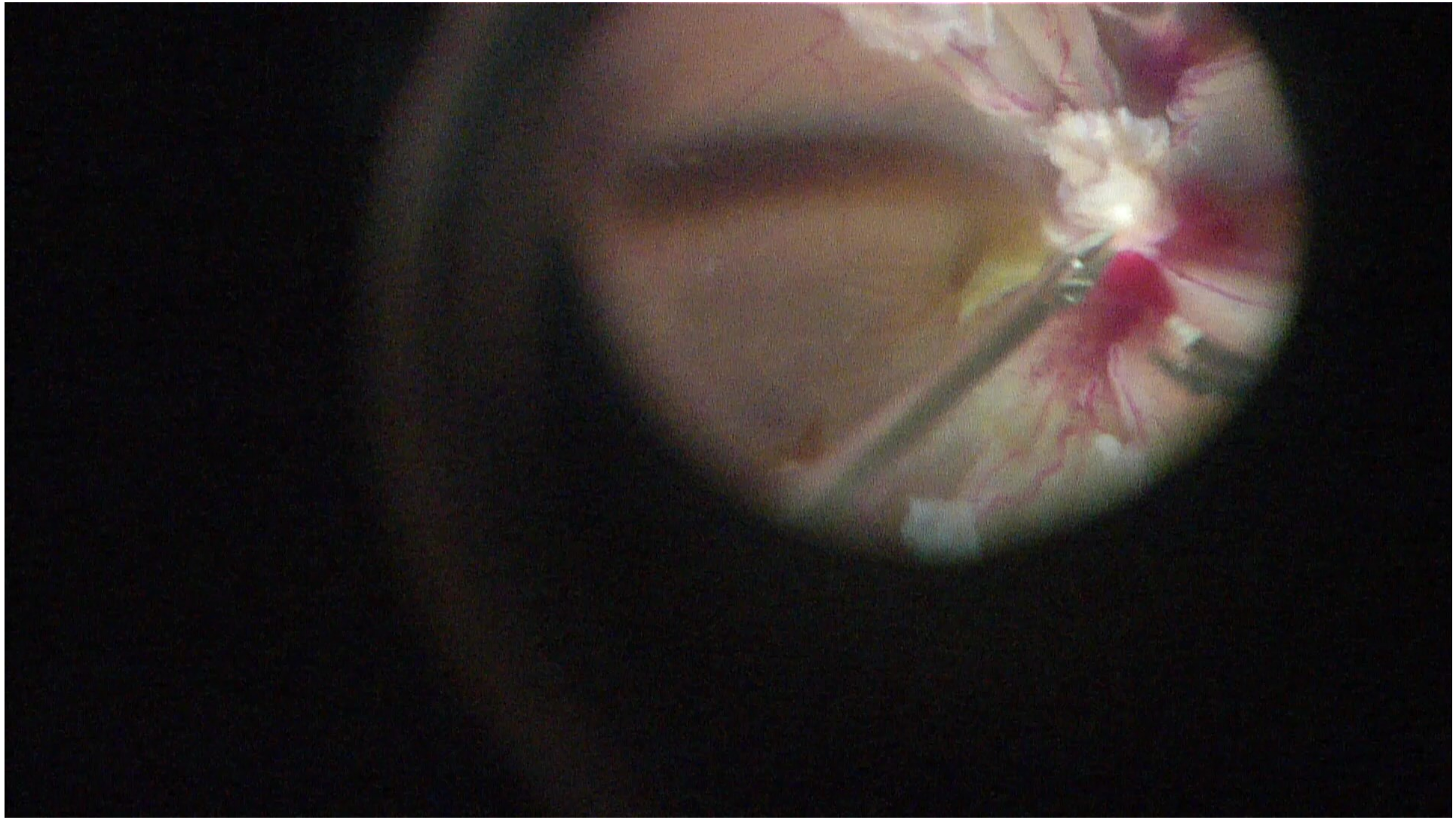

Université de Paris

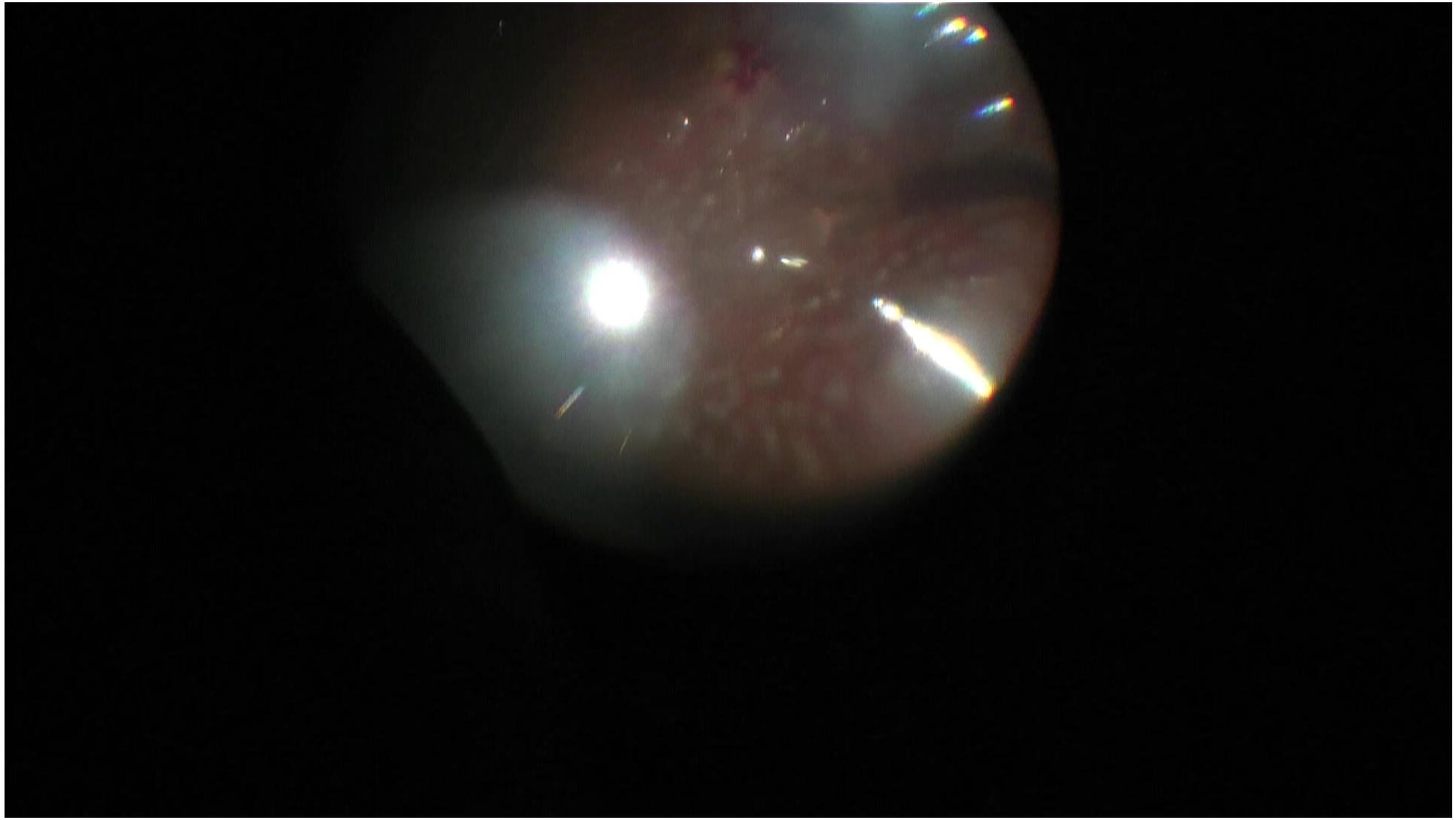

Université de Paris

« Retirer Membrane »



Université de Paris

La technique

G30% : 5 ml dans 500 ml BSS

- Laisser le cristallin +++
- Pas de tamponnement si DR tractionnel pur sans déhiscences per opératoires
- En cas de déhiscence:
  - Gaz de préférence
  - Silicone si nécessité de pexie post-opératoire ou forme à risque de re-prolifération secondaire
- PPR systématique en fin d'intervention jusqu'à l'ora
- Anti-VEGF en adjuvant en pré- et per-opératoire

Laisser le cristallin !

G30% : 5 ml dans 500 ml BSS

Retina. 2014 Oct;34(10):1960-8. doi: 10.1097/IAE.0000000000000171.

Visual outcomes from pars plana vitrectomy versus combined pars plana vitrectomy, phacoemulsification, and intraocular lens implantation in patients with diabetes.

Silva PS[1], Diala PA, Hamam RN, Arrigg PG, Shah ST, Murtha TL, Schlossman DK, Cavallerano JD, Sun JK, Aiello LP.

Author information

Abstract

PURPOSE: To compare visual acuity outcomes and diabetic retinopathy progression after pars plana vitrectomy (PPV) versus combined pars plana vitrectomy and phacoemulsification (PPVCE) in patients with diabetes.

METHODS: Retrospective review of 222 consecutive diabetic patients undergoing PPV or PPVCE.

RESULTS: A total of 251 eyes of 222 patients were evaluated (PPV = 122, PPVCE = 129). Four-year follow-up was 64% (161 eyes). Overall, patient undergoing PPVCE had better preoperative visual acuity (PPVCE = 20/80, PPV = 20/160, P = 0.03). At 4-year follow-up, visual acuity improved (PPV = +22, PPVCE = +11 letters) compared with baseline in both groups. After correcting for baseline differences in visual acuity, no statistically significar difference in final visual acuity was observed (PPVCE = 20/32, PPV = 20/50, P = 0.09). Results did not differ substantially by surgical indication (vitreous hemorrhage, traction retinal detachment, epiretinal membrane, and/or diabetic macular edema). Cataract progression occurred in 64%, anc cataract surgery was performed in 39% of phakic eyes undergoing PPV. Rates of diabetic retinopathy progression, vitreous hemorrhage, and retinal detachment were not statistically different. Neovascular glaucoma developed in 2 patients (2%) after PPV and 6 patients (8%) after PPVCE (P = 0.07).

CONCLUSION: In diabetic patients, equivalent visual acuity improvement over 4 years was observed after PPV or PPVCE. Visual outcomes and retinopathy progression rates were not significantly different after either intervention, suggesting that PPVCE may be appropriate when indicated in patients with diabetes.

Université de Paris

Tamponnement ?

- Pas de tamponnement si DR tractionnel pur sans déhiscences per opératoires

The outcomes of pars plana vitrectomy without endotamponade for tractional retinal detachment secondary to proliferative diabetic retinopathy
Eur J Ophthalmol. 2014 Jan-Feb;24(1):107-13. doi: 10.5301/ejo.5000305. Epub 2013 May 15.

- Rôle de l'OCT per op pour vérifier ?
- Le liquide sous rétinien met très longtemps à se résorber… rétinotomie de drainage ??

- Gaz de préférence
- Silicone à visée optique si monophtalme, nécessité de pexie post op sur déhiscences…. Ou forme à risque de re-prolifération secondaire

Université de Paris

Gas Tamponade for the Prevention of Postoperative Vitreous Hemorrhaging After Diabetic Vitrectomy: A Randomized Clinical Trial

Rush B et al. Am J Ophthalmol 2022 Oct;242:173-180.

- **Methods:**
  - PDR subjects requiring PPV for the indication of non-clearing VH
  - prospectively randomized
  - Group A subjects underwent 20% to 30% SF6 gas tamponade,
  - Group B subjects : BSS

- The primary outcome was the incidence of postoperative VH during the 6-month trial period.

- **Results:**
  - 96 subjects included.
  - Postoperative VH in 6 of 54 subjects in **Group A (SF6) (11.1%)** and 14 of 42 in **Group B (BSS) (33.3%) (P = .008**).
  - Unplanned PPV during the trial period for postoperative VH occurred in 2 of 54 in Group A (3.7%) and 6 of 42 in Group B (14.2%) (P = .06).
  - The mean BCVA was not significantly different at 6-months follow-up between groups (P = .58)

Outcomes of Pars Plana Vitrectomy with Panretinal Photocoagulation for Treatment of Proliferative Diabetic Retinopathy Without Retinal Detachment: A Seven-Year Retrospective Study

Patel at al. Clin Oph 2023

- 81 eyes of 81 patients (mean age of 62.1 ± 10.5 years).
- At a median follow-up of 18 months:
  - VH (12.3%),
  - diabetic macular edema (DME) (12.3%),
  - ocular hypertension (8.6%),
  - RD (4.9%),
  - need for additional PPV (6.2%).
- Eyes with **PRP performed within 6 months before surgery** had a lower frequency of developing postoperative VH (5.3%) compared to eyes that received PRP more than 6 months before surgery (27.3%, $P = 0.04$).
- Eyes that received **preoperative anti-vascular endothelial growth factor (VEGF)** treatment (2.0%) had a lower frequency of postoperative VH compared to eyes that did not receive anti-VEGF treatment (14.3%, $P = 0.04$).

VITRECTOMY FOR DIABETIC COMPLICATIONS

A Pooled Analysis of Randomized Controlled Trials Using Modern Techniques and Equipment

RYAN B. RUSH, MD,*†‡§ SLOAN W. RUSH, MD,†‡ ROBERT M. REINAUER, MD,*¶
PEDRO GOMEZ BASTAR, MD,* DAVID J. BROWNING, MD, PHD**

Methods: There were 943 subjects who prospectively underwent small-gauge PPV with antivascular endothelial growth factor pretreatment for proliferative diabetic retinopathy–related complications and completed 6-month follow-up.

Postoperative Variable	Outcome (n = 943)
Best-corrected visual acuity at 6 months (logMAR)	Median 1.00 IQR (0.50, 1.30)
Intraocular pressure >30 mmHG during the trial period*	Yes = 104 (11.0%)
Postoperative complication secondary to PDR occurring during the trial period	Yes = 199 (21.1%) No = 744 (78.9%)
Type of postoperative complication secondary to PDR	Persistent VH = 80 (40.3%) Recurrent VH = 44 (22.3%) New RD = 23 (11.4%) Recurrent RD = 26 (13.1%) NVG = 26 (13.1%)†
Postoperative complication unrelated to PDR occurring during the trial period	Yes = 47 (5.0%) No = 896 (95.0%)
Type of postoperative complication unrelated to PDR	Corneal decompensation = 4 (8.5%) Cyclitic membrane = 3 (6.4%) Macular epiretinal membrane = 23 (48.9%) Hypotony = 2 (4.3%) Hyphema = 2 (4.3%) IOL subluxation = 5 (10.6%) Macular hole = 7 (14.9%) Subretinal fluid = 1 (2.1%)
Unplanned secondary vitrectomy during the trial period	Yes = 86 (9.1%) No = 857 (90.9%)
DME treated with one or more anti-VEGF injections during the trial period	Yes = 104 (11.0%) No = 839 (89.0%)

Université de Paris

Pratiquer ou compléter la PPR systématiquement à la fin de toute vitrectomie diabétique +++

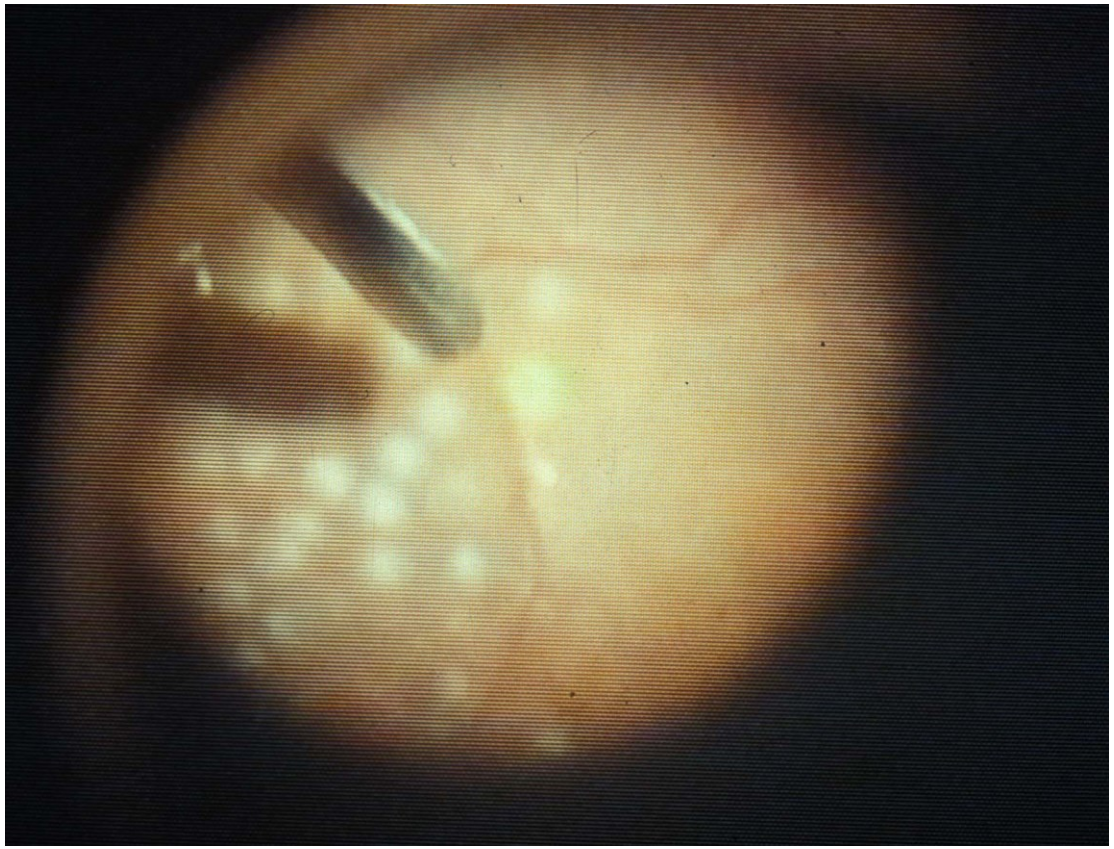

Université de Paris

Les anti-VEGFs

- Facilite le geste chirurgical
  - Rôle pro-fibrotique qui facilite la dissection
  - Diminue le saignement per-opératoire
- Diminue le risque de récidive hémorragique et reprolifération post-opératoire

⇒IVT 2 – 5 jours maximum avant la vitrectomie pour RDP + injecter en per-opératoire

- Risque de « Crunch syndrome » [1]

1. Tan et al. Surv Ophthalmol. Nov-Dec 2021;66(6)

Université de Paris

Adjuvants à la vitrectomie :
Anti-VEGF (Avastin, Lucentis, Aflibercept)

- Poids moléculaire Avastin x 3 Lucentis
- Lucentis et Aflibercept pénètrent mieux la rétine et la choroïde
- 1/2 vie intra-vitréenne Avastin > Lucentis > Afli
- Passage systémique Avastin > Afli> Lucentis
- => 4-5 j maximum avant la vitrectomie pour RDP (risque de rétraction)

AMERICAN ACADEMY OF OPHTHALMOLOGY®

Ranibizumab Plus Panretinal Photocoagulation versus Panretinal Photocoagulation Alone for High-Risk Proliferative Diabetic Retinopathy (PROTEUS Study)

João Figueira, MD, PhD,[1,2,3] Emily Fletcher, MB ChB, FRCOphth,[4] Pascale Massin, MD, PhD,[5] Rufino Silva, MD, PhD,[1,2,3,6] Francesco Bandello, MD, PhD,[7] Edoardo Midena, MD, PhD,[8] Monica Varano, MD,[9] Sobha Sivaprasad, MD, FRCOphth,[10] Haralabos Eleftheriadis, MD,[10] Geeta Menon, MBBS, MS,[11] Miguel Amaro, MD,[12] Sarah Ayello Scheer, MD, PhD,[13] Catherine Creuzot-Garcher, MD, PhD,[14] João Nascimento, MD,[15] Dalila Alves, MSc,[1] Sandrina Nunes, PhD,[1] Conceição Lobo, MD, PhD,[1,2,3] José Cunha-Vaz, MD, PhD,[1] for the EVICR.net Study Group*

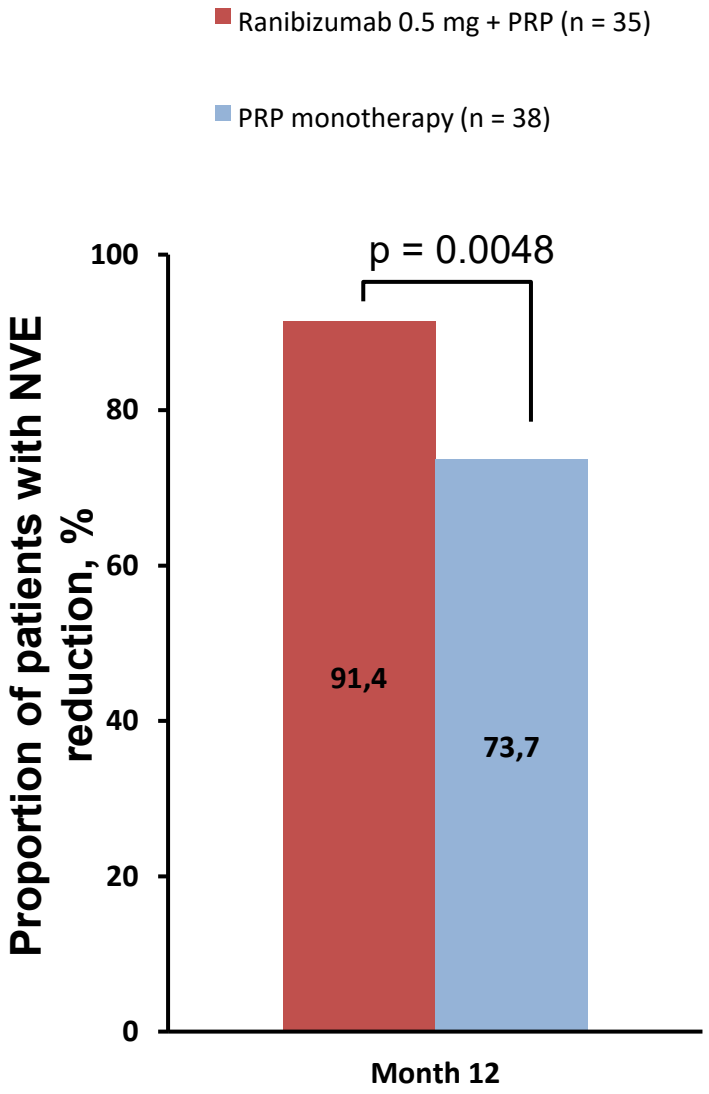

Université de Paris

Intérêt potentiel anti-VEGF dans la RDP sévère

- Facilite le geste chirurgical dans le traitement de la RDP
  - Rôle pro fibrotique (facilite la dissection)
  - Diminue le saignement per op (rétraction des néovx)
- Stop l'envahissement intra-oculaire secondaire par les néovaisseaux
- Diminue la récidive hémorragique post opératoire

=> 4 – 5 jours maximum avant la vitrectomie pour RDP (risque de rétraction)

Crunch syndrome

- Contraction brutale de la hyaloïde postérieure et de la fibrose, augmentant les forces de tractions
- en moyenne 13 j après IVT
- 5 à 18% selon les séries
- Facteurs de risque :
  - absence de PPR pré-opératoire
  - prolifération fibrovasculaire arciforme autour du pôle postérieur

Tan et al. Surv Ophthalmol. Nov-Dec 2021;66(6)

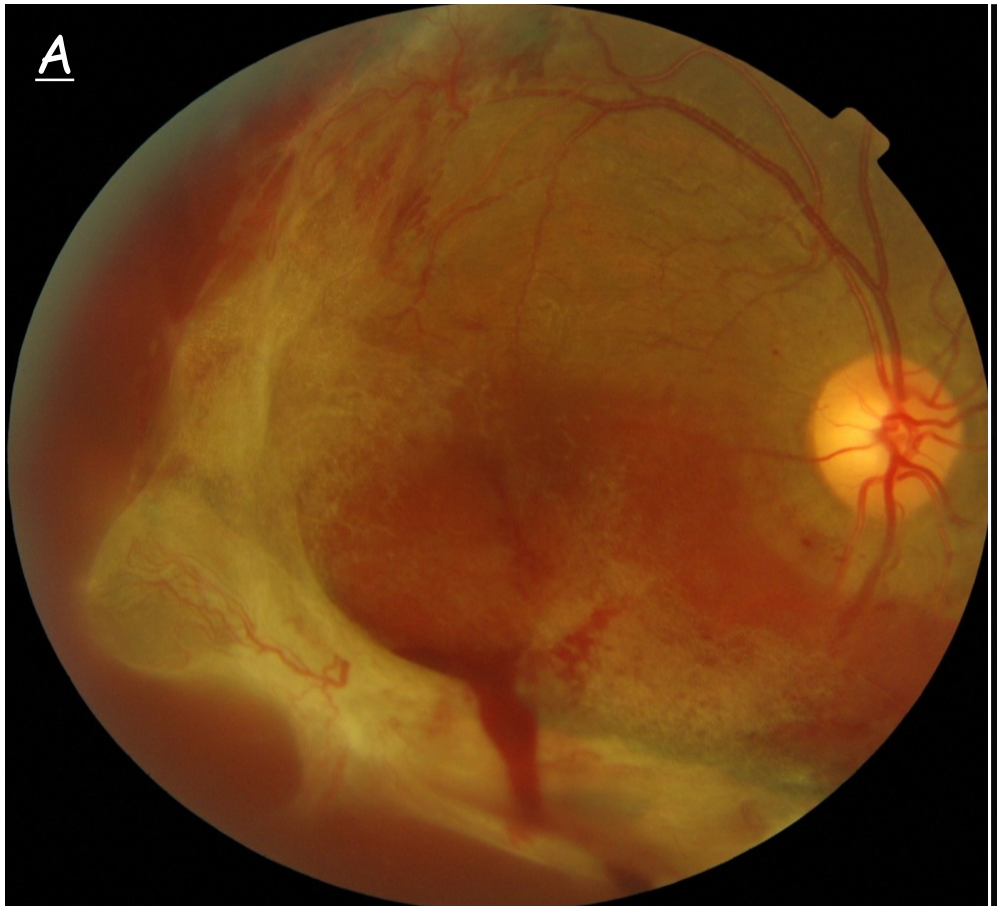

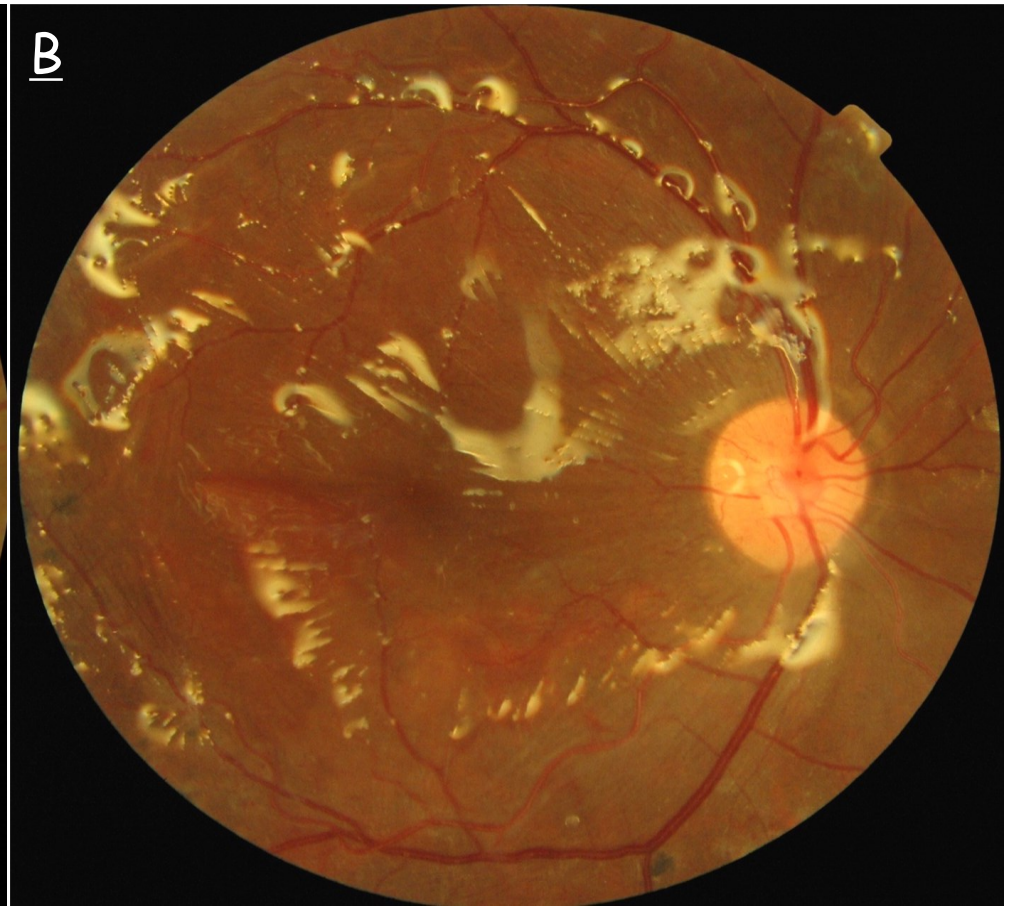

Université de Paris

Complications post-opératoires de la vitrectomie

1. Récidive de l'hémorragie intra-cavitaire
2. Glaucome néovasculaire, Prolifération fibrovasculaire antérieure
3. Endophtalmie, Cataracte, Décollement de la rétine
4. Réaction inflammatoire postopératoire (réaction fibrinoïde)

IVT seule pour une HdV ?

JAMA | Original Investigation

Effect of Intravitreous Aflibercept vs Vitrectomy With Panretinal Photocoagulation on Visual Acuity in Patients With Vitreous Hemorrhage From Proliferative Diabetic Retinopathy

A Randomized Clinical Trial

Andrew N. Antoszyk, MD; Adam R. Glassman, MS; Wesley T. Beaulieu, PhD; Lee M. Jampol, MD; Chirag D. Jhaveri, MD; Omar S. Punjabi, MD; Hani Salehi-Had, MD; John A. Wells III, MD; Maureen G. Maguire, PhD; Cynthia R. Stockdale, MSPH; Daniel F. Martin, MD; Jennifer K. Sun, MD, MPH; for the DRCR Retina Network

JAMA. 2020;324(23):2383-2395. doi:10.1001/jama.2020.23027

STUDY DESIGN

- Multi-centre (39 sites in US and Canada)
- Unmasked (investigator + patient)
- 2 year follow-up
- n = 205

INCLUSION CRITERIA

- Adults with type 1 or 2 diabetes
- Vitreous haemorrhage from proliferative diabetic retinopathy causing vision impairment

EXCLUSION CRITERIA

- Known diabetic macular oedema
- Tractional retinal detachments involving or threatening the macula
- Neovascular glaucoma
- Prior vitrectomy

Vitrectomy + PRP Group

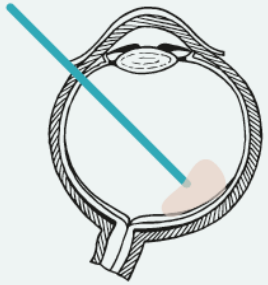

n = 105

Within 2 weeks of randomization:

1. Vitrectomy + PRP

If vitreous haemorrhage fails to clear 4 weeks post-surgery:

2. Aflibercept (2 monthly) ± 4 weekly at discretion of investigators

If vitreous haemorrhage fails to clear following 2 aflibercept injections:

3. Repeat vitrectomy

Aflibercept Group

n = 100

1. Injection at baseline, 4, 8, 12 weeks
2. Injection at 16 weeks (Deferred if complete fundus viewable with absent neovascularisation)
3. Injection at 24 weeks (Unless eye has stabilised i.e. unchanged for 2 consecutive visits)

From 16 weeks if persistent vitreous haemorrhage following 2 monthly injections:

4. Vitrectomy

Université de Paris

IVT seule pour une HdV ?

JAMA | Original Investigation

Effect of Intravitreous Aflibercept vs Vitrectomy With Panretinal Photocoagulation on Visual Acuity in Patients With Vitreous Hemorrhage From Proliferative Diabetic Retinopathy

A Randomized Clinical Trial

Andrew N. Antoszyk, MD; Adam R. Glassman, MS; Wesley T. Beaulieu, PhD; Lee M. Jampol, MD; Chirag D. Jhaveri, MD; Omar S. Punjabi, MD; Hani Salehi-Had, MD; John A. Wells III, MD; Maureen G. Maguire, PhD; Cynthia R. Stockdale, MSPH; Daniel F. Martin, MD; Jennifer K. Sun, MD, MPH; for the DRCR Retina Network

JAMA. 2020;324(23):2383-2395. doi:10.1001/jama.2020.23027

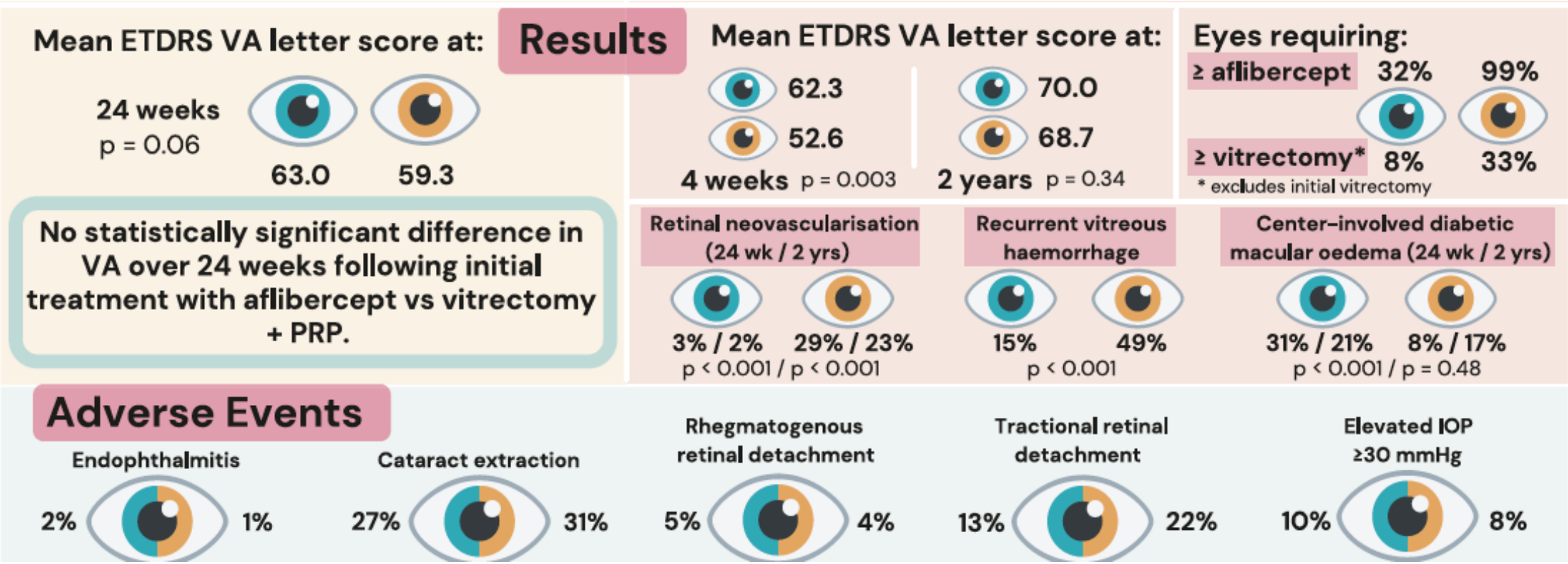

Université de Paris

Chirurgie d’un patient diabétique

1. RDP compliquée: HdV, DRT
2. OM tractionnel
3. OM non tractionnel ?
4. Cataracte diabétique

Place de la vitrectomie

- **Traction vitréo-maculaire antéro-postérieure évidente**
  - Indication de vitrectomie
- **Traction tangentielle liée à une membrane**
  - Vitrectomie uniquement en cas de réponse incomplète aux IVT

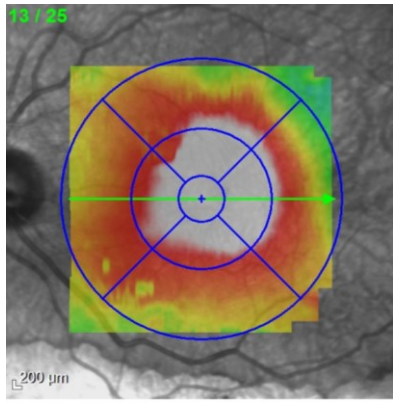

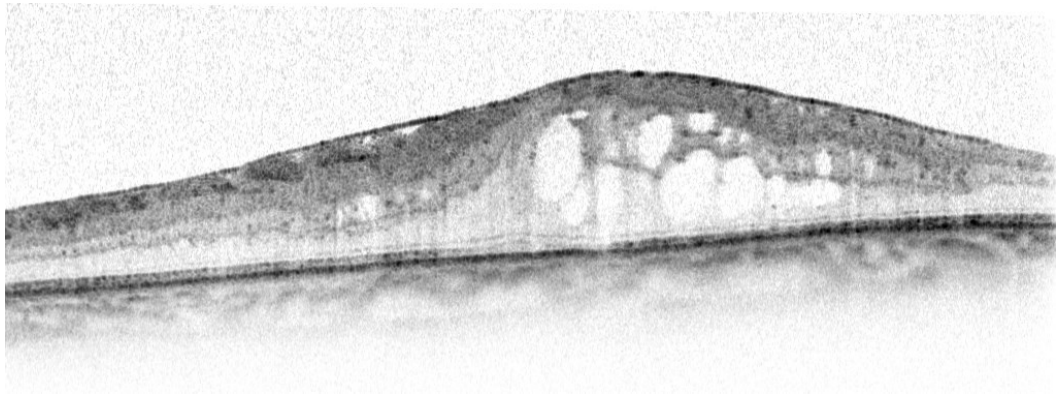

- **En l'absence de traction**
  - À réserver aux cas non répondeurs aux IVT : amélioration anatomique mais rarement fonctionnelle

Schmidt-Erfurth U, Garcia-Arumi J, Bandello F, et al. Guidelines for the Management of Diabetic Macular Edema by the European Society of Retina Specialists (EURETINA). Ophthalmologica. 2017;237(4):185-222.

Homme 57 ans
DT2 depuis 12 ans
Mal équilibré (ne connaît pas son HbA1c)
surpoids
PPR ODG en 2007

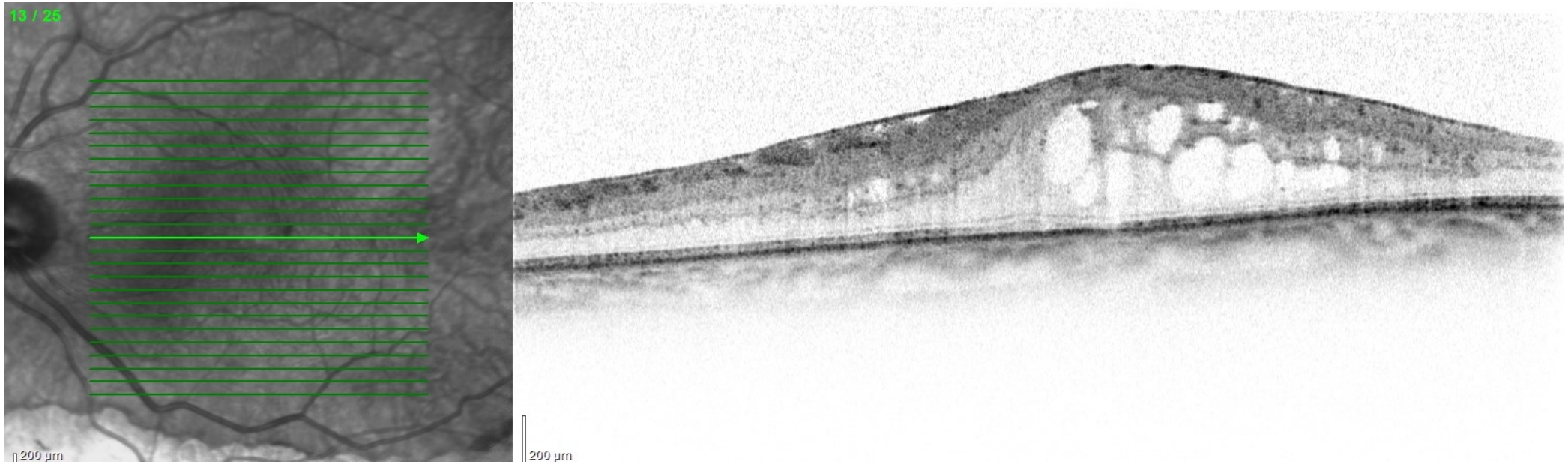

AV 2/10e

Université de Paris

1 mois post IVT OZURDEX



AV 5/10e

Université de Paris

OM tractionnel

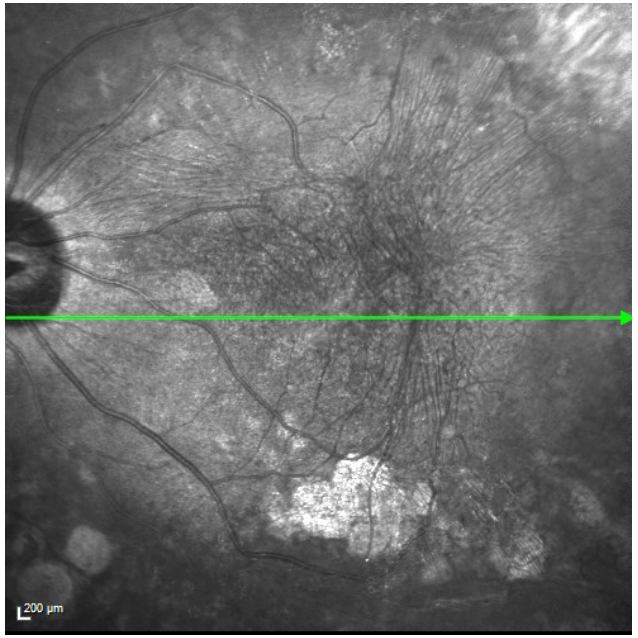



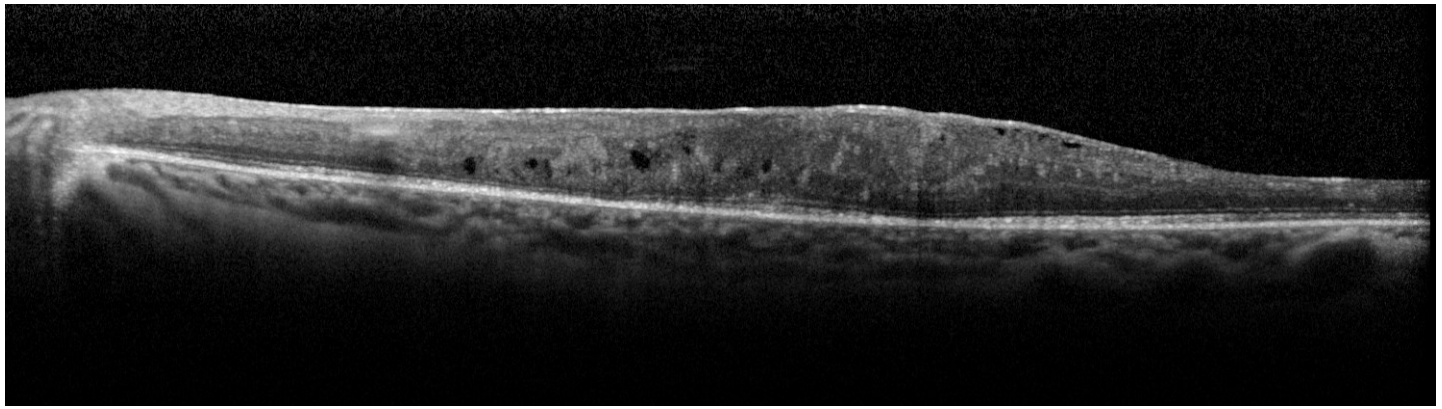

Université de Paris

F 31 ans
DT1 équilibré
Monophtalme OG (DRT OD), vitrectomisé, phaque
Adressée OMD OG
AV = 1/10ème

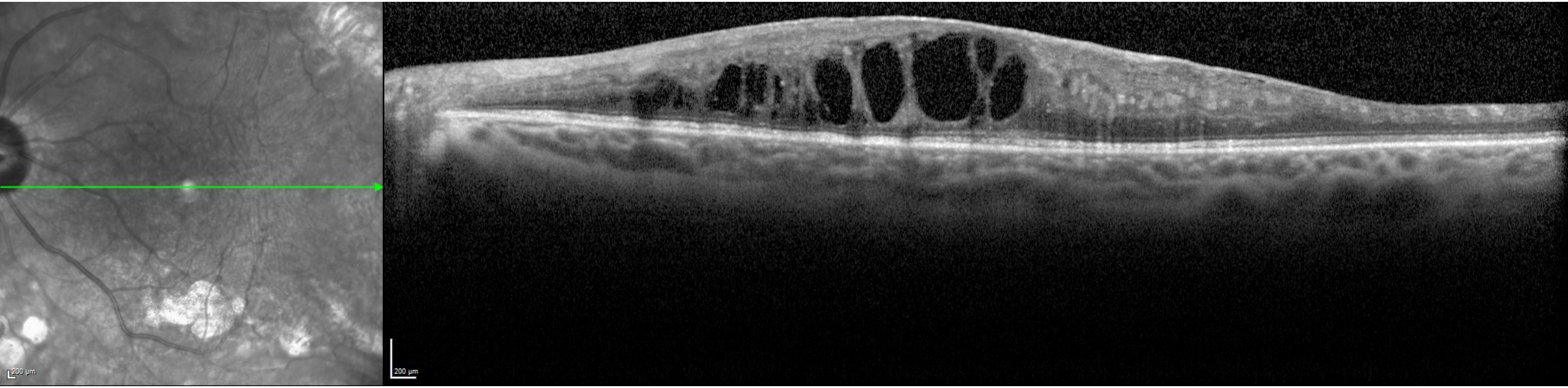

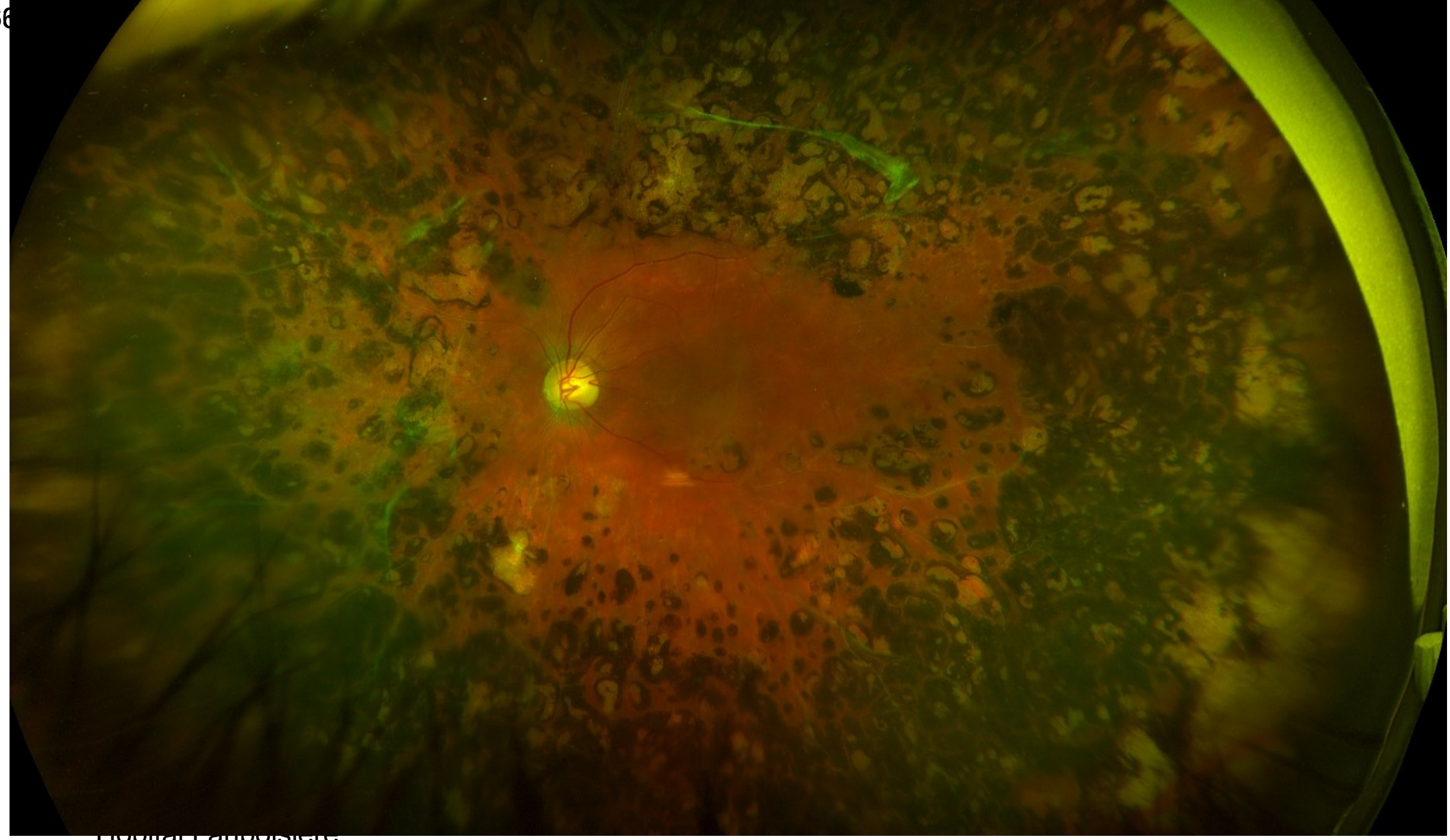

Hopital Lanboisiere

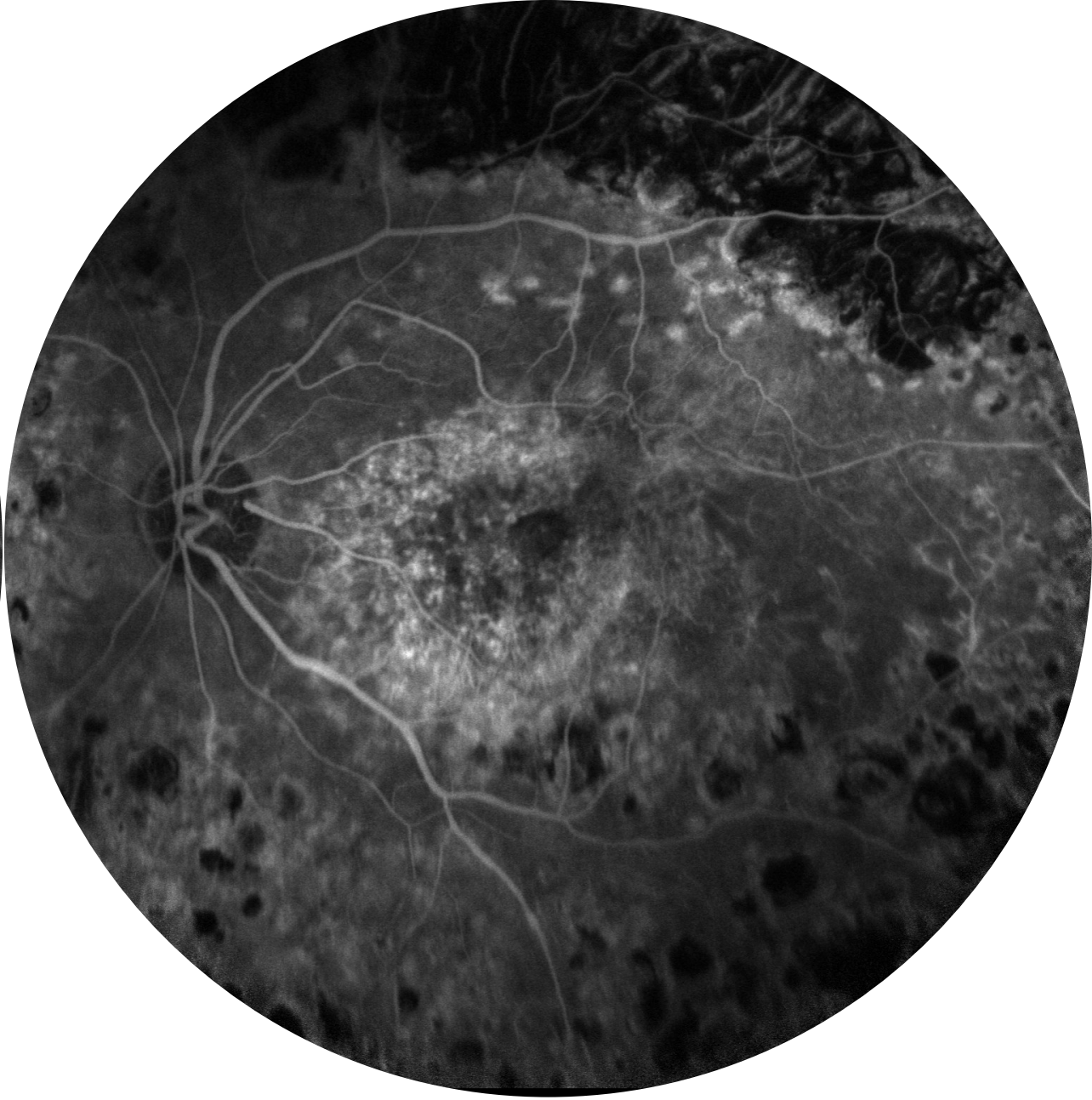

Université de Paris

Implant DEXAMETHASONE

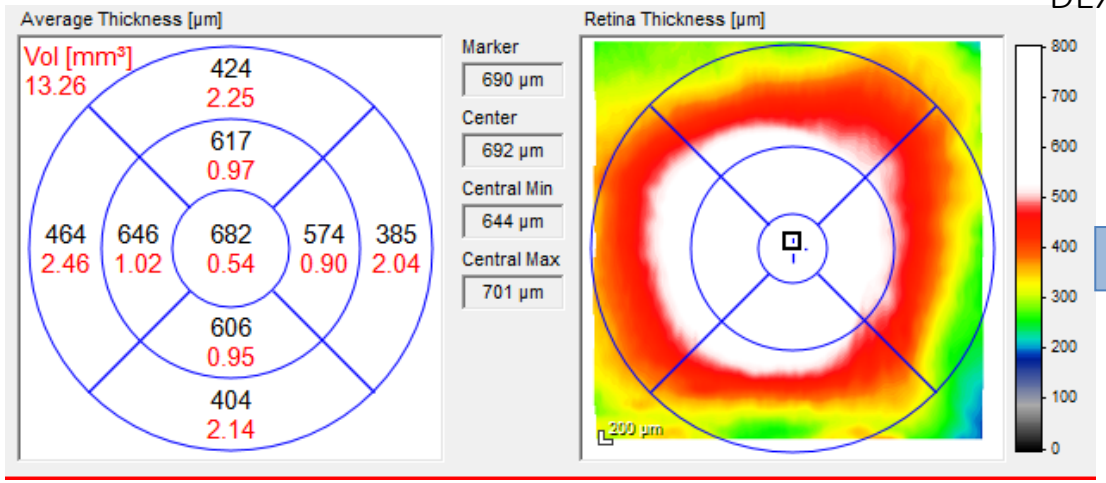

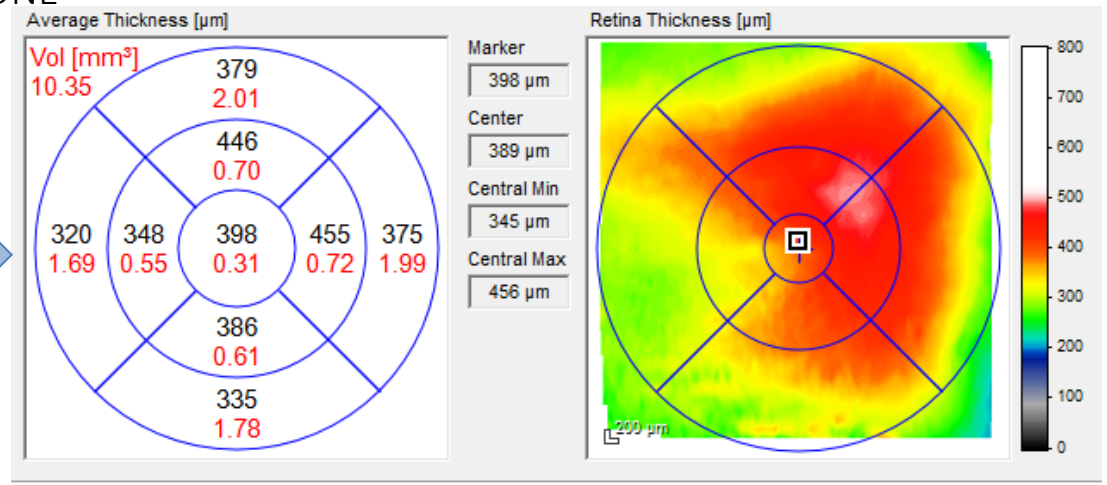

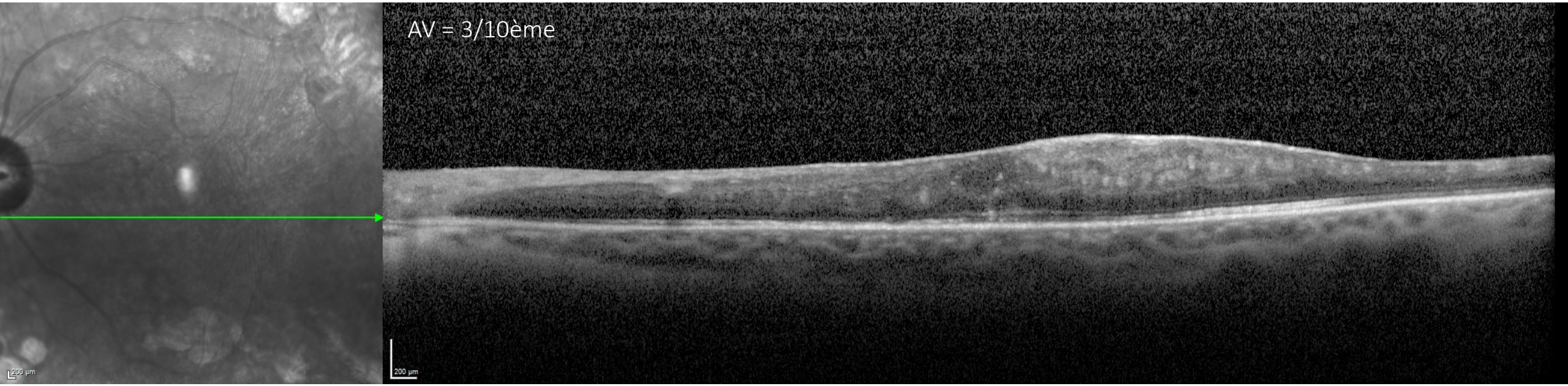

Université de Paris

M4 post IVT d'implant de DEXAMETHASONE
AV = 1/10ème
EMC 688 microns

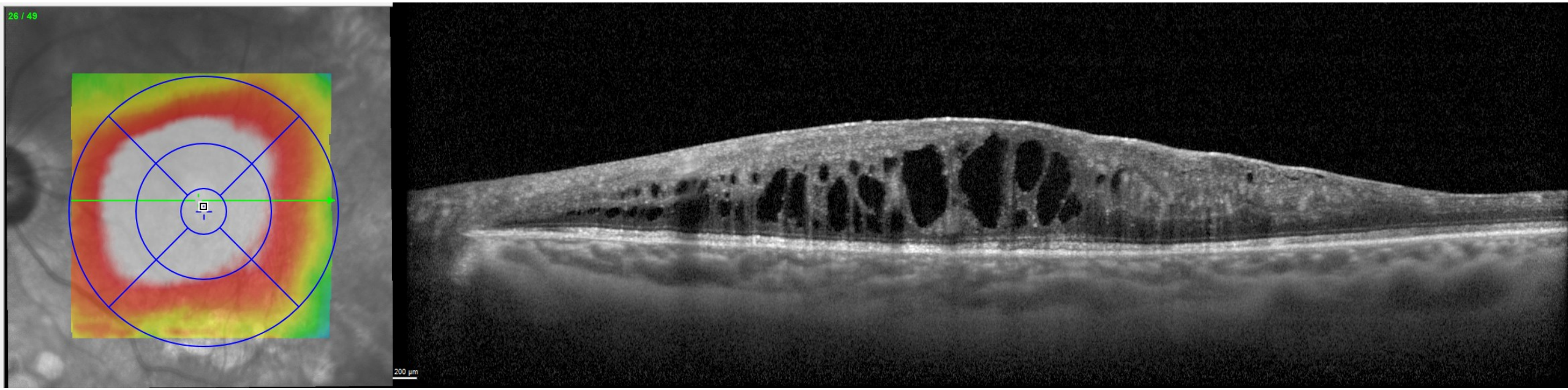

M2 post IVT n° 2 d'implant de DEXAMETHASONE
AV = 3/10ème
EMC 382 microns

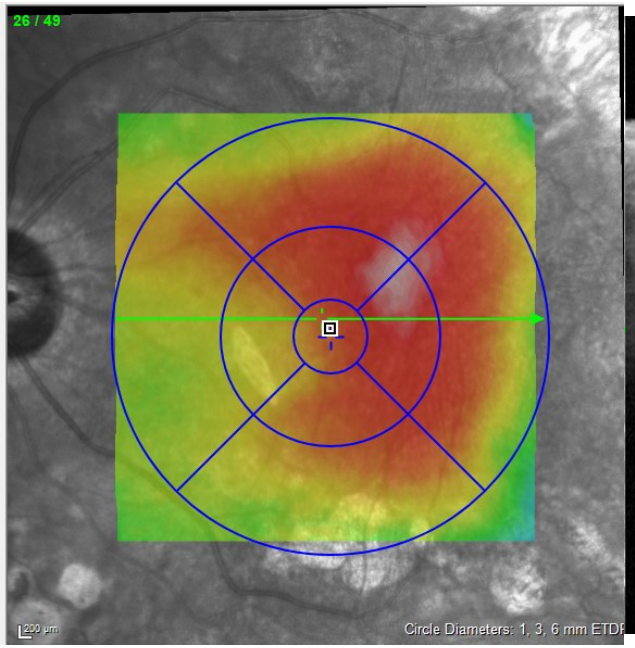

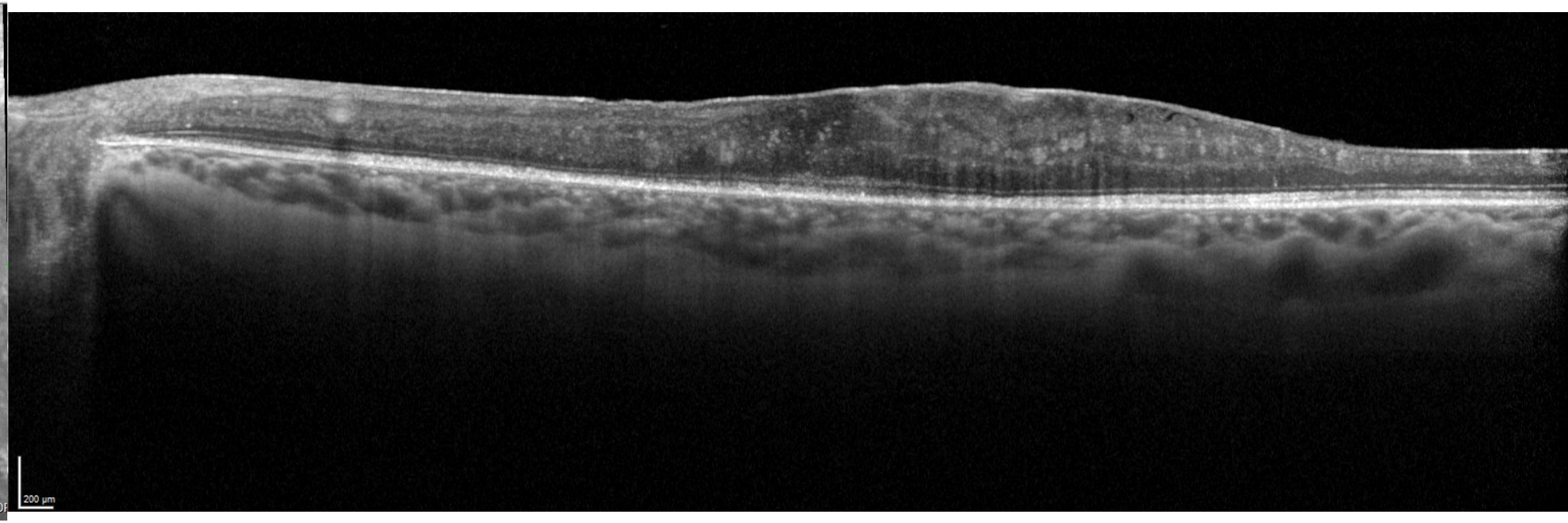

Université de Paris

M2 post IVT n° 5 d'implant de DEXAMETHASONE
AV = 2/10ème
EMC 435 microns

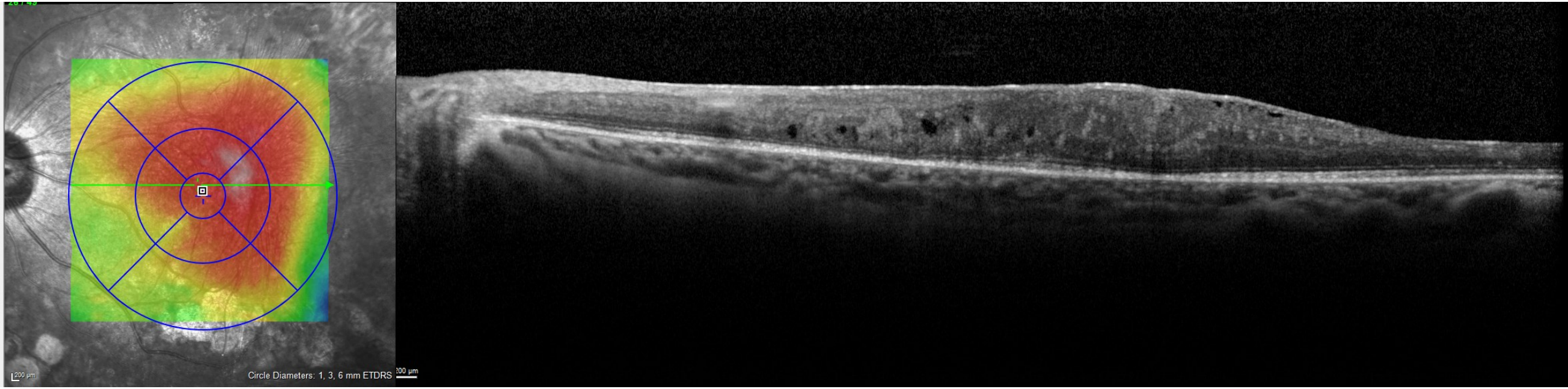

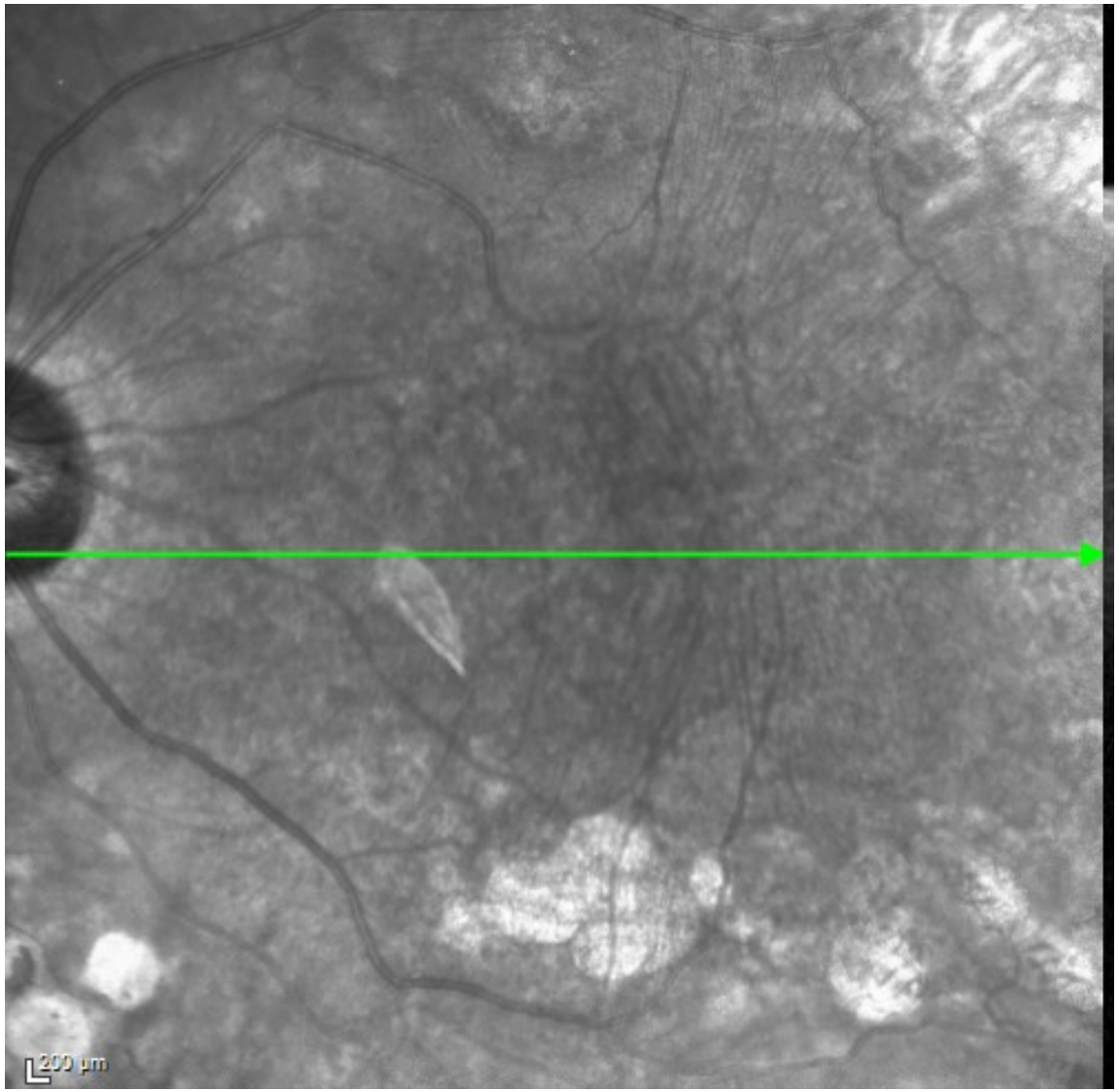

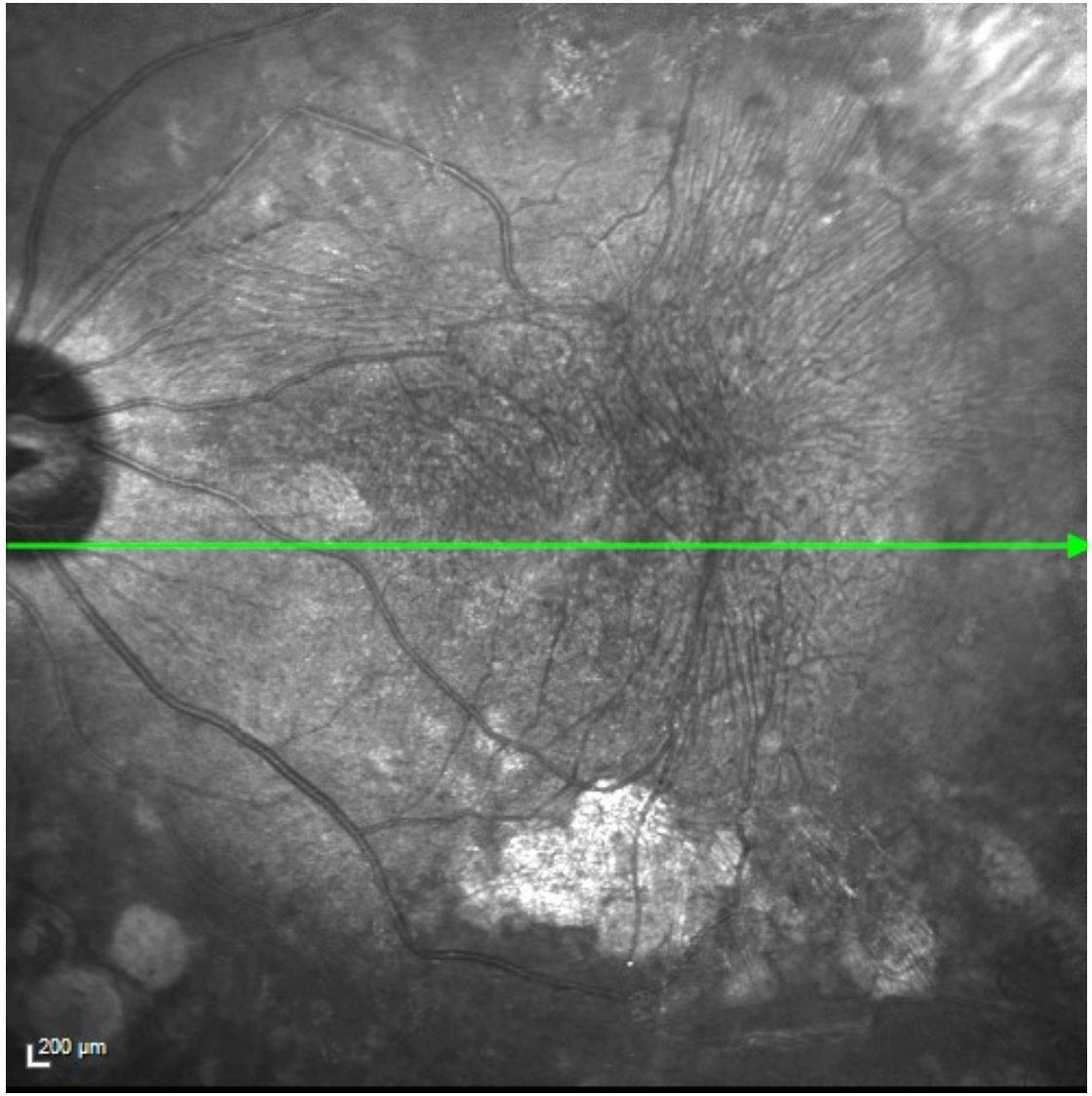

Hôpital Lariboisière

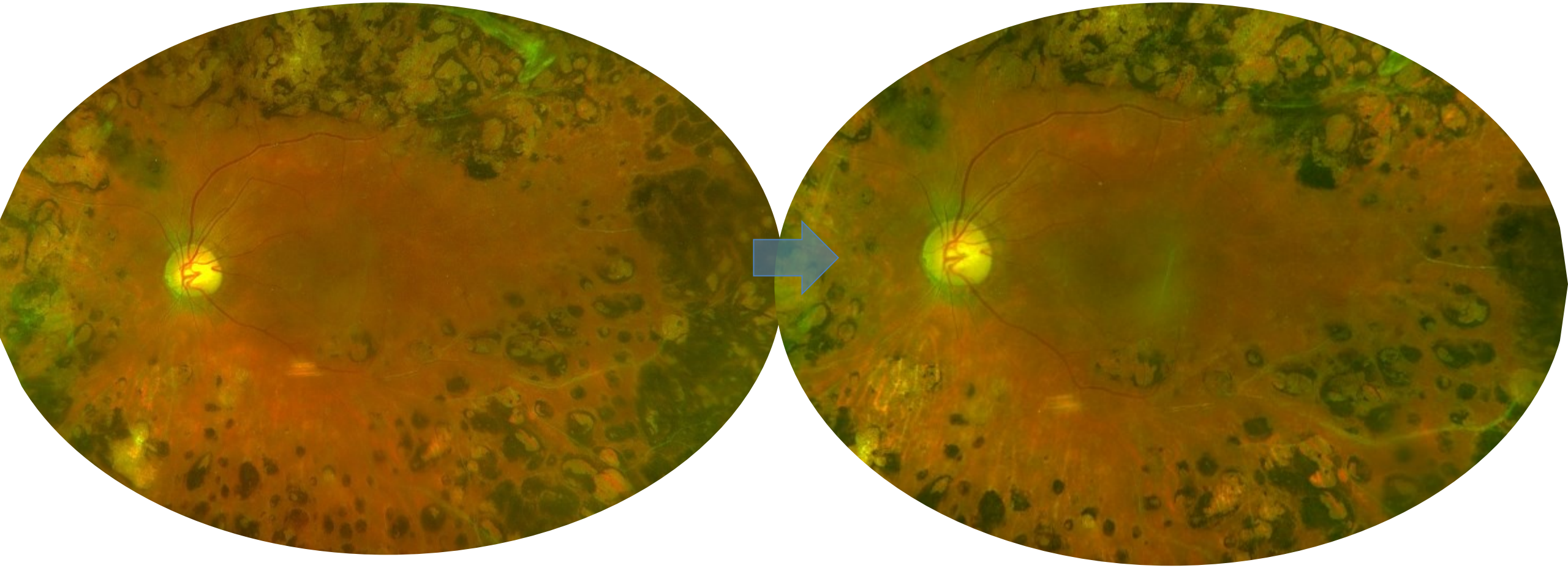

Université de Paris

M4 post IVT n° 5 d'implant de DEXAMETHASONE
AV = 1/10ème
EMC 682 microns

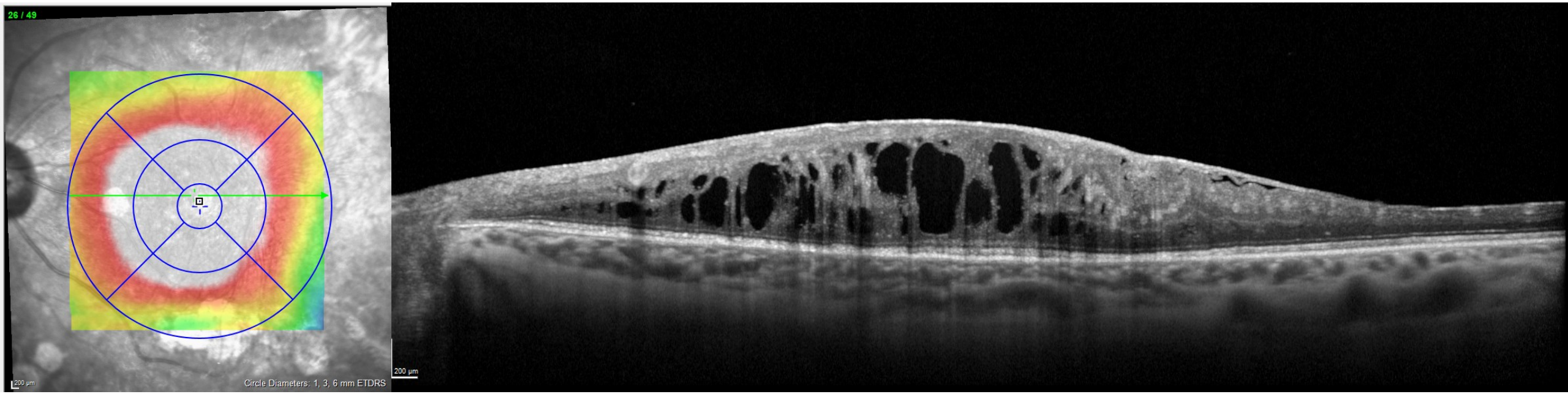

IVT + Vitrectomie

Université de Paris

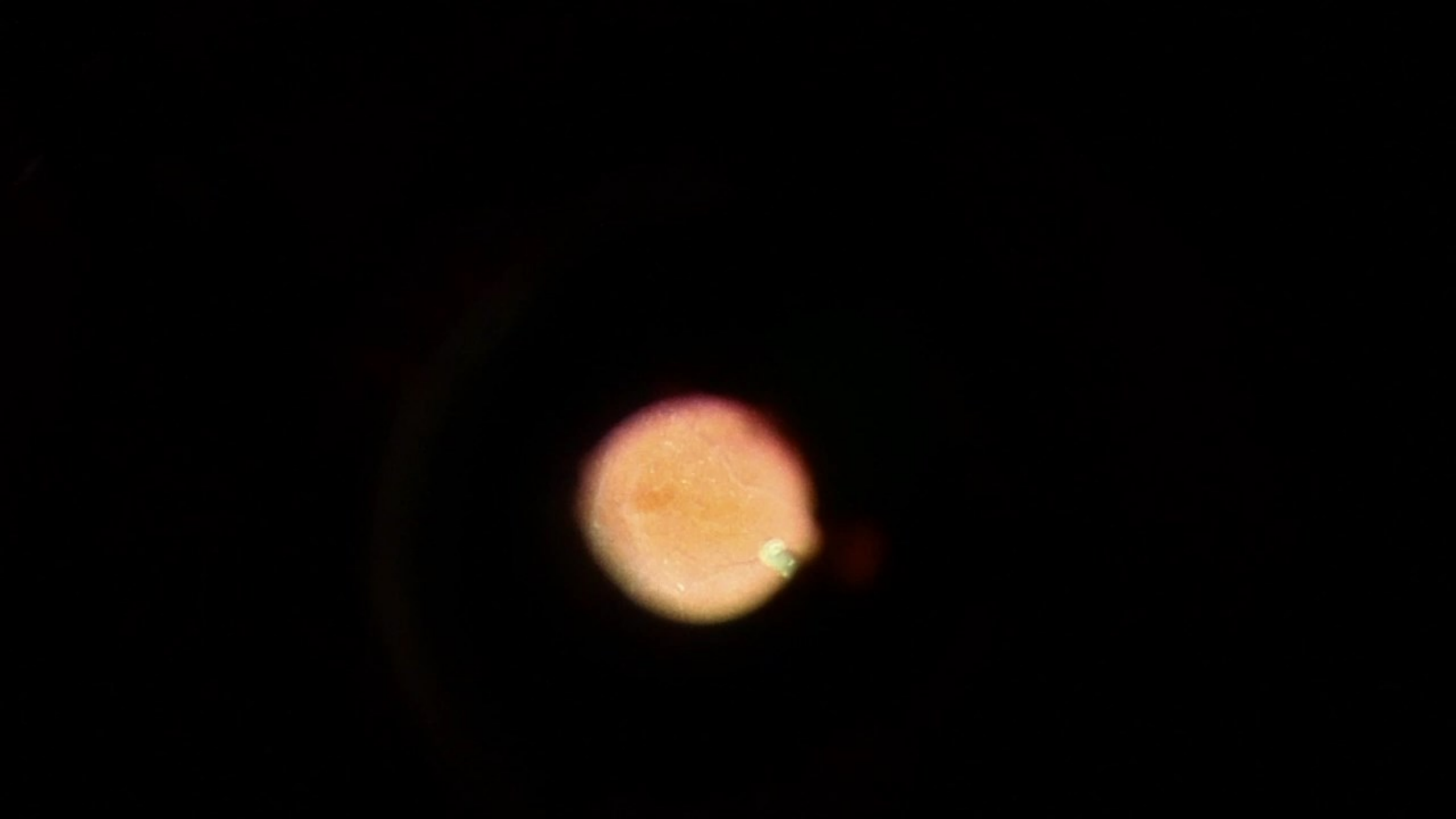

M4 post-opératoire
M6 post IVT DEX implant
Pas de récidive
AV = 4/10ème

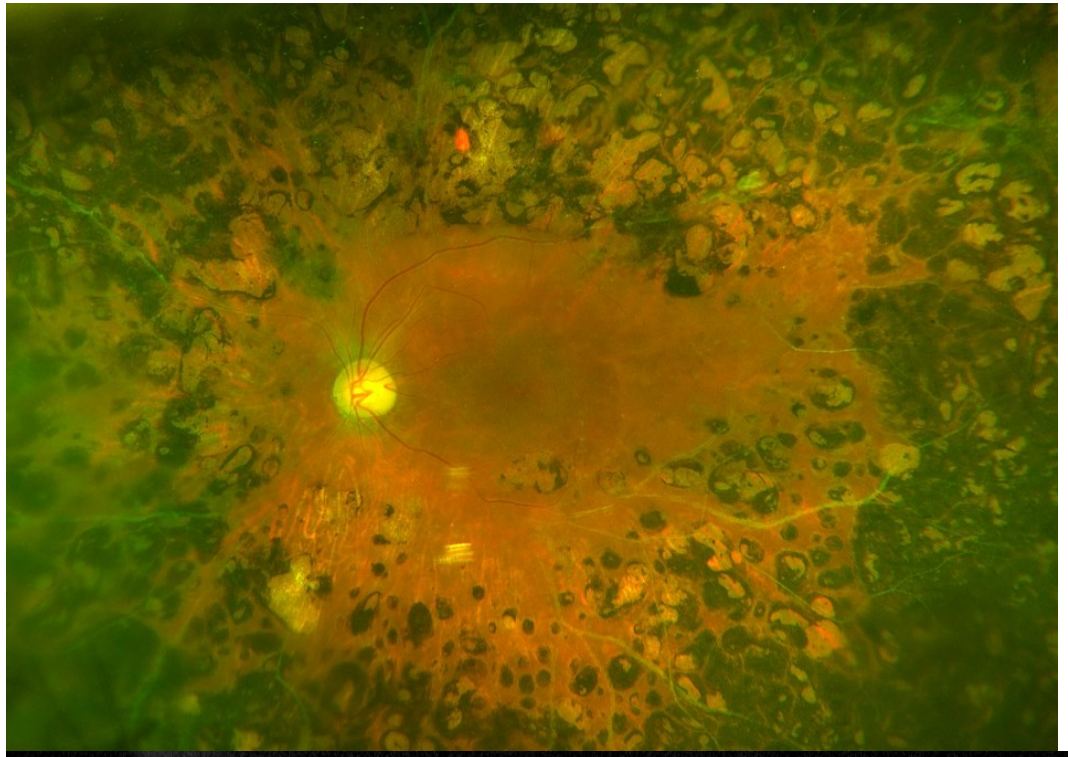

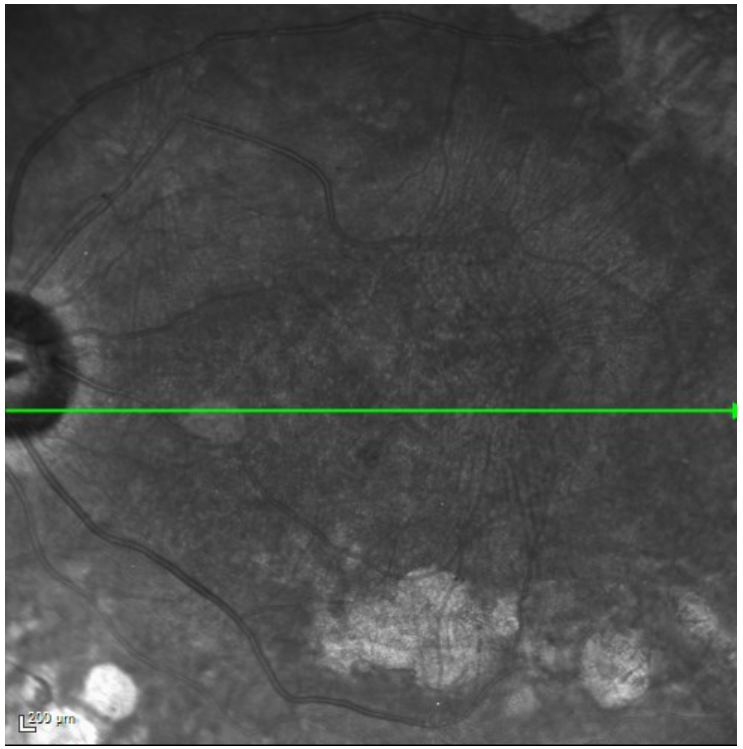

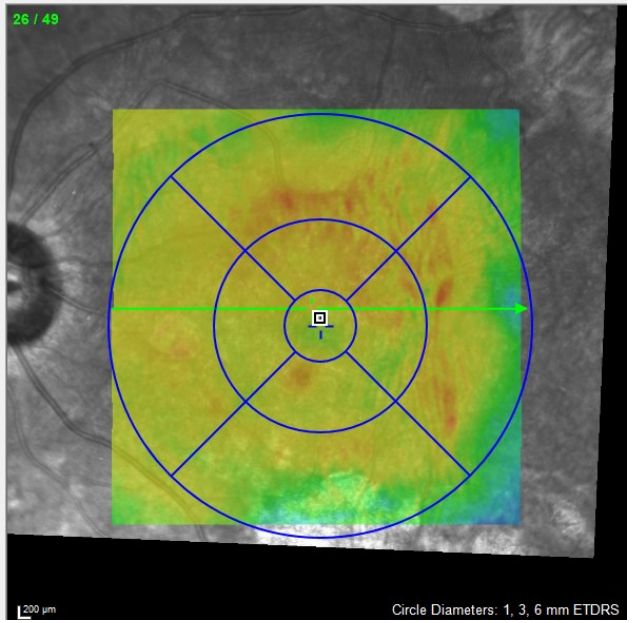

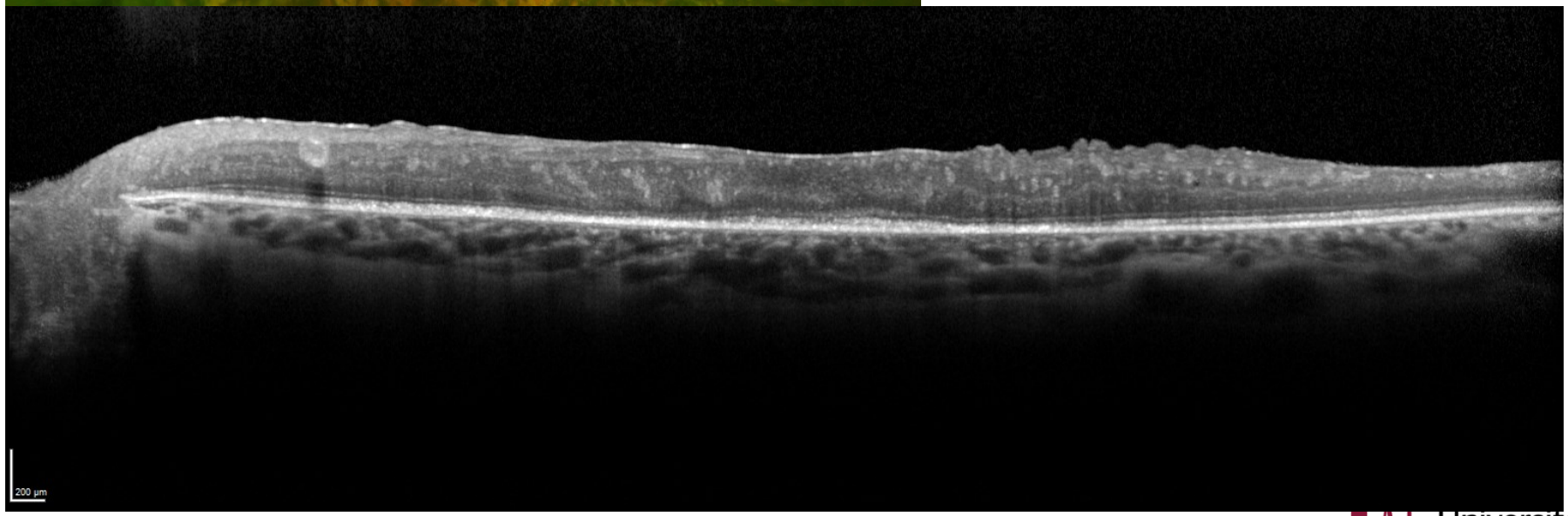

Le pelage de la limitante interne?

- Dans la RD proliférante: diminution du risque de MER secondaire et d'OMD à 6 mois ? [1]

- Dans l'OMD tractionnel : résultats discordants, pas de preuve du bénéfice. [2]

1. Rush et al. Retina 2021 May 1;41(5):1118-1126.
2. Nakajima et al. Review. Retina 2015 Sep;35(9):1719-25.

Université de Paris

Chirurgie d’un patient diabétique

1. RDP compliquée: HdV, DRT
2. OM tractionnel
3. OM non tractionnel ?
4. Cataracte diabétique

Chirurgie de cataracte et OMD

- Stabiliser l’OM avant d’envisager la chirurgie de la cataracte !

Cataracte diabétique

OMD traité depuis plusieurs mois

OMD naïf

Pas d'OM ni antécédent d'OM

PKE-ICP avec IVT pré- ou per-op

Traitement OMD AVANT PKE-ICP

Pas d'IVT

3 à 5 IVT anti-VEGF

1 IVT Ozurdex

Anti-VEGF:
IVT per-op ou PKE à 1 semaine de la dernière IVT

Ozurdex:
IVT per op ou opérer à M1-M2 de la dernière IVT

Pas d'OZURDEX si rupture ou ICP clippé iris

Poursuite des IVT en post op, suivi mensuel pendant 2 à 3 mois
Traitement local prolongé : AINS 1 mois + corticoïdes 1 mois

Université de Paris

Et la périphérie ?

- La chirurgie de cataracte aggrave la RD dans les 6 à 12 mois post-op, d'autant plus que la RD est avancée

- Si RDNP sévère ou néovaisseaux (RDP ou OVCR ischémique)
  - Faire le maximum de PPR pré-op
  - PKE + IVT (plutôt anti-VEGF que corticoides)
  - Compléter PPR en post-op rapidement (dès 1 mois post-op)

Chirurgie RD, *à retenir*

La technologie moderne + anti VEGF repousse les limites chirurgicales chez le diabétique, mais les risques de perte visuelle post opératoires sont encore réels…

- Sujet JEUNE / RD floride : PRUDENCE !!!! Privilégier l'AG et différer des quelques jours plutôt que d'opérer en urgence dans de mauvaises conditions
- JAMAIS d'urgence à opérer en DR diabétique sauf si composante rhegmatogène associée
  - Laisser le cristallin si possible
  - Toujours faire le Maximum de PPR en pré opératoire
  - Anti-VEGF en péri opératoire (pré -op, per-op et post-op)
- Savoir QUAND NE PAS OPERER : RISQUES de CECITE POST OP
  - BAV ancienne profonde, surtout si vision ambulatoire résiduelle
  - Ischémie majeure, vaisseaux déshabités, rubéose irienne
  - Monophtalme ?
- La chirurgie de cataracte combinée aggrave l'OMD et la RD périphérique = bien contrôler l'absence de RI en PO
- Surveiller l'œil adelphe et suivi rapproché en post opératoire

Université de Paris

Hôpital Lariboisière
Hôpital Saint Louis
AP-HP.Nord

Merci pour votre attention

aude.couturier@aphp.fr

Université de Paris